

Radiation dermatitis grading ATLAS for clinical trials

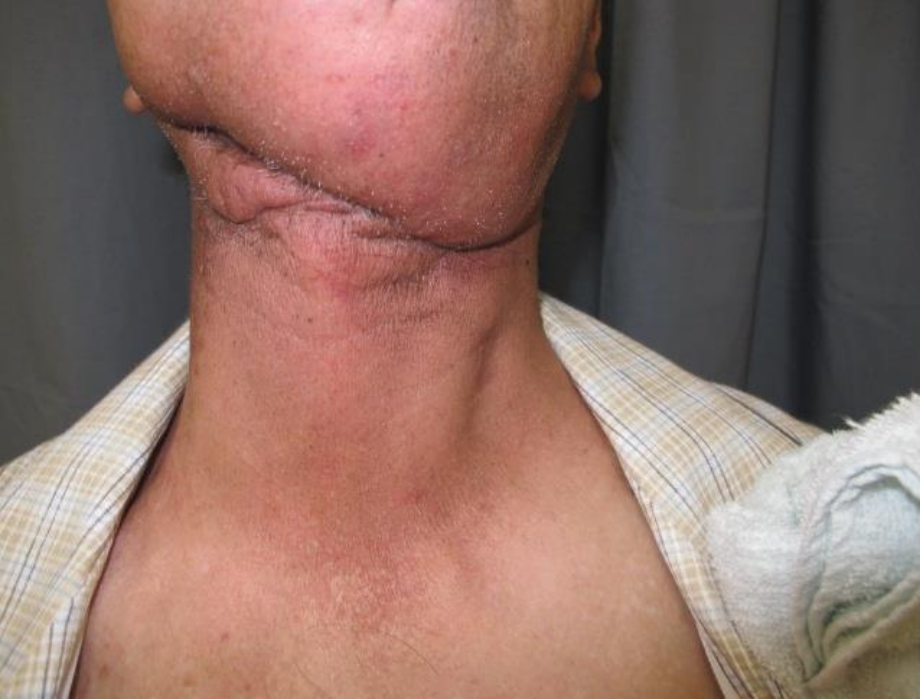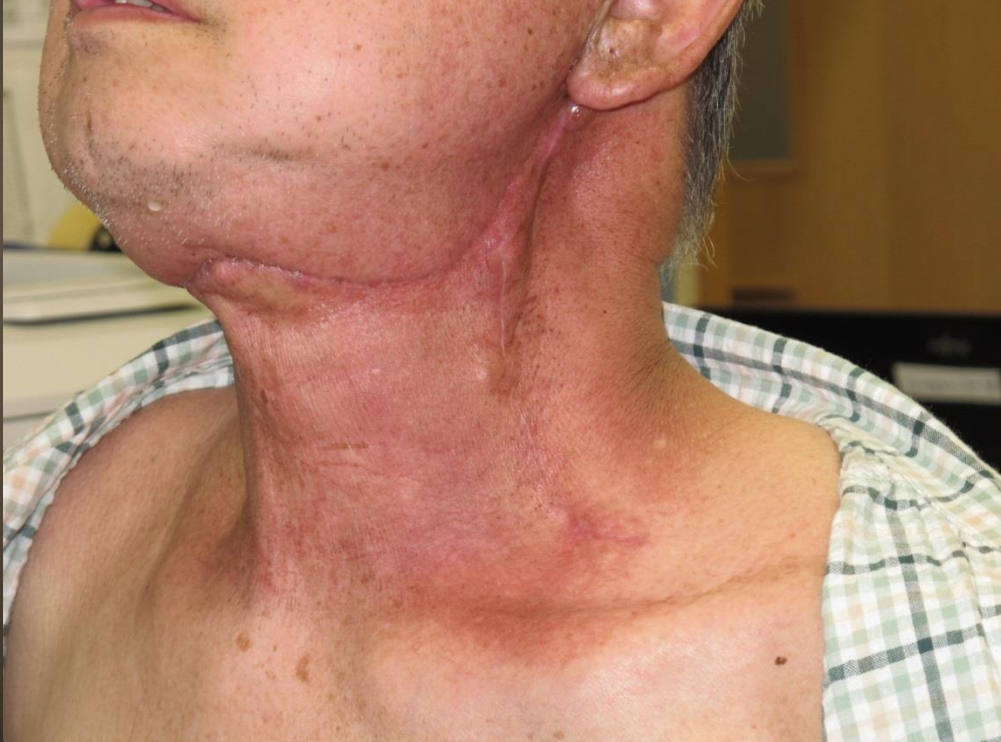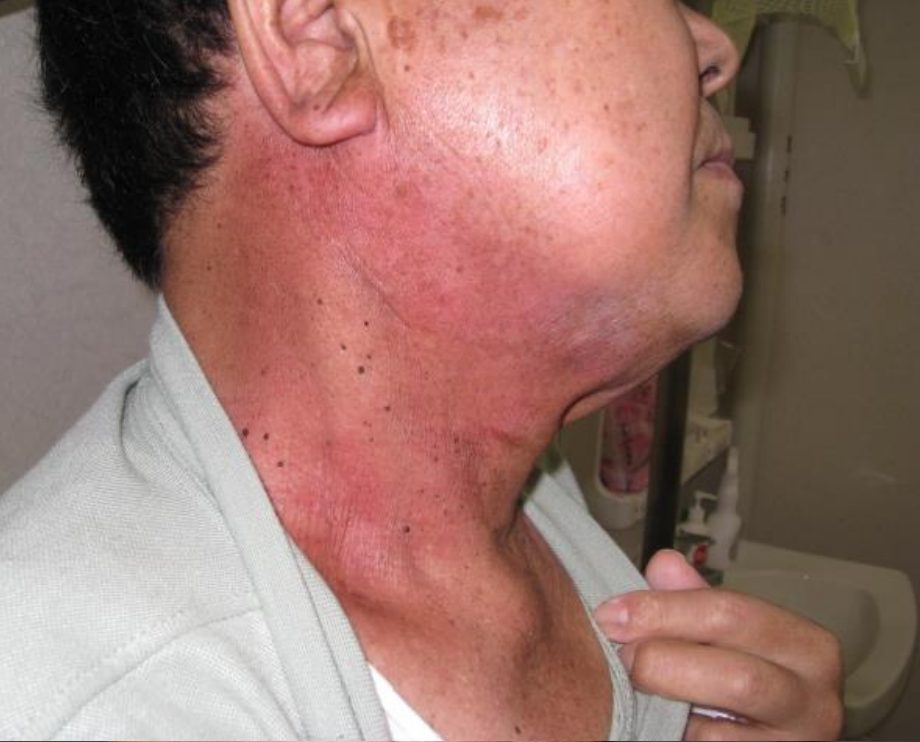(RD grading ATLAS)

English version

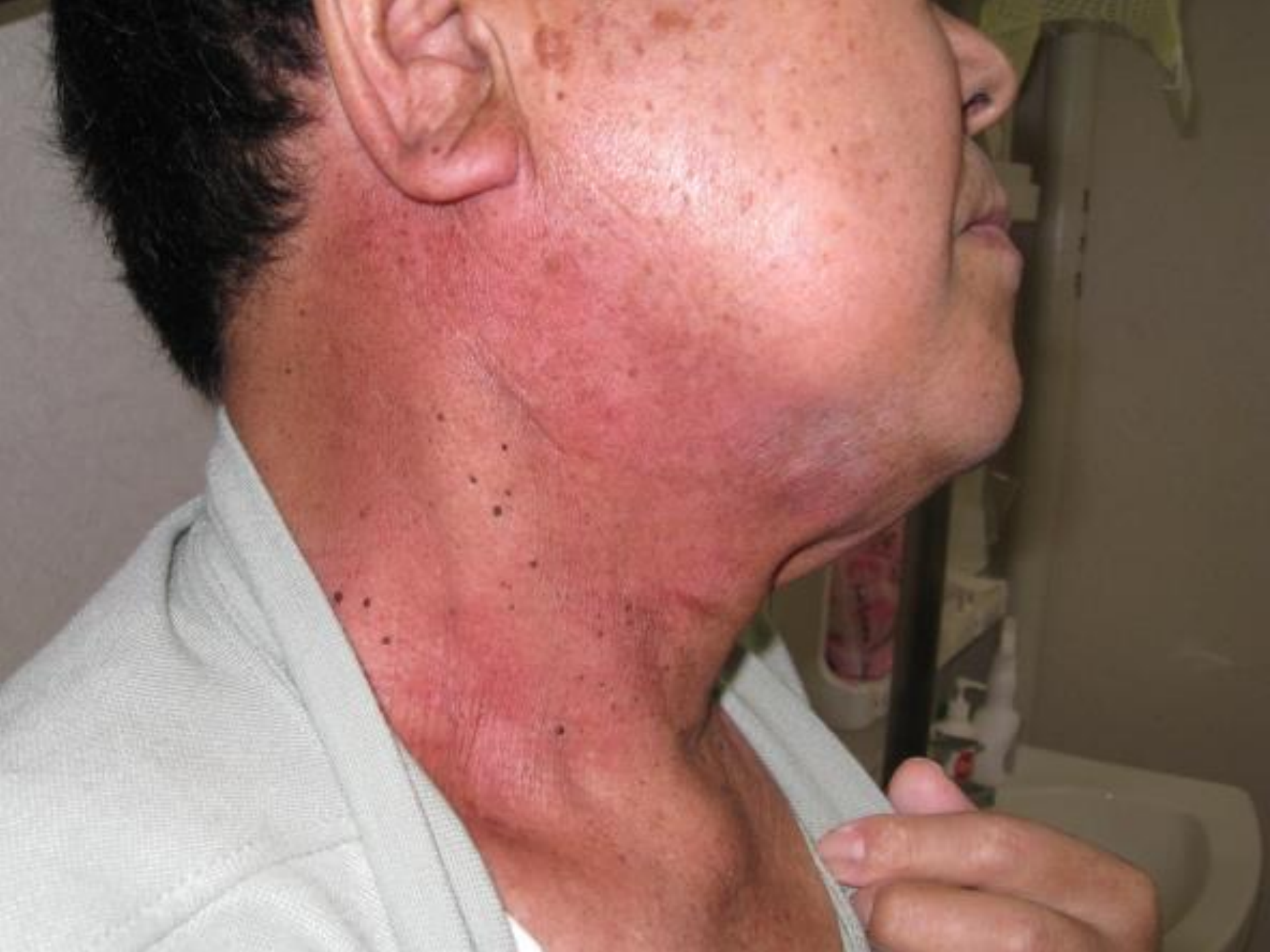August. 26. 2015	Ver 1.0
September. 1. 2015	Ver 1.01
September. 15. 2015	Ver 1.02
October. 15. 2015	Ver 1.03

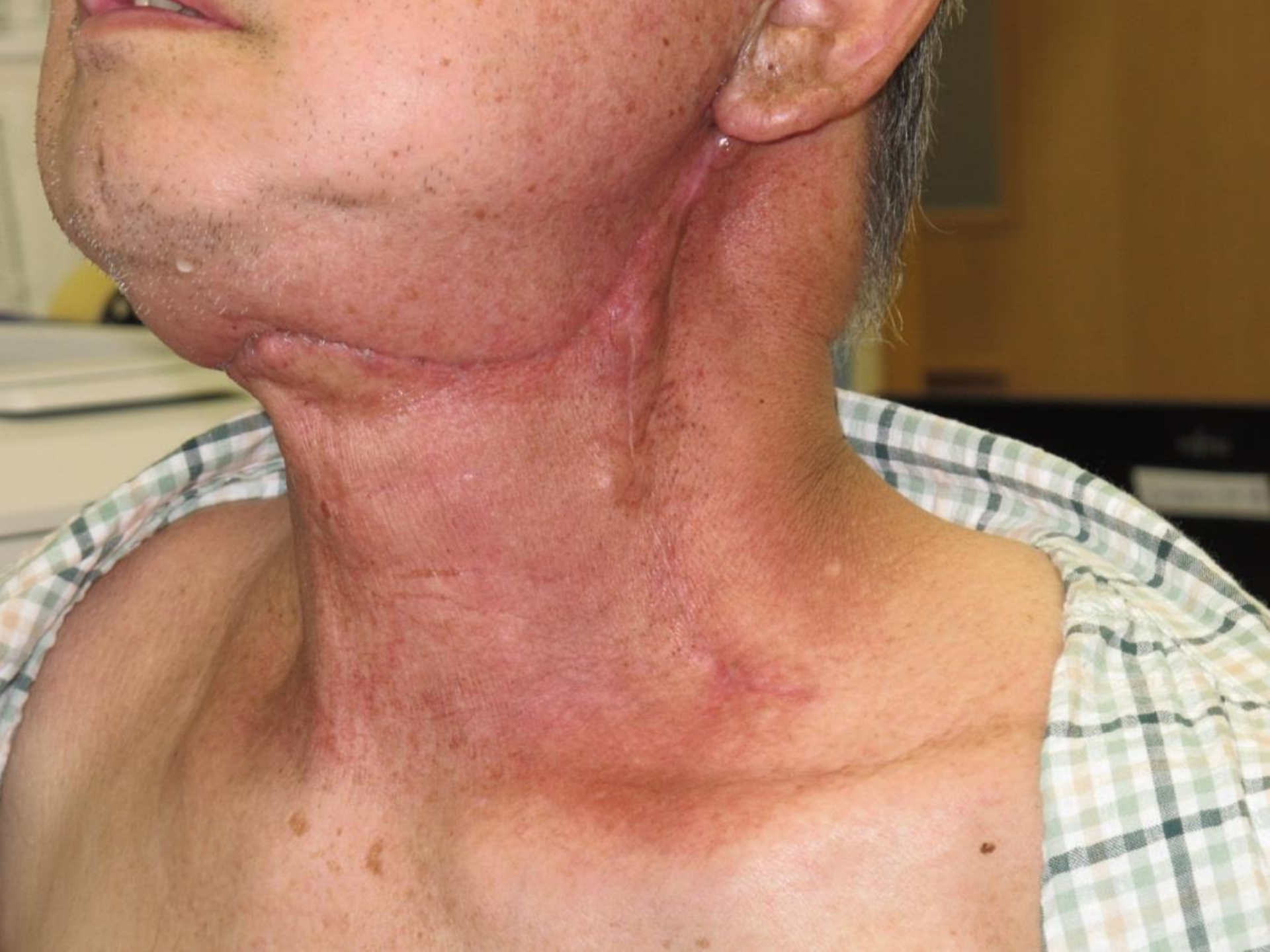Grade.1

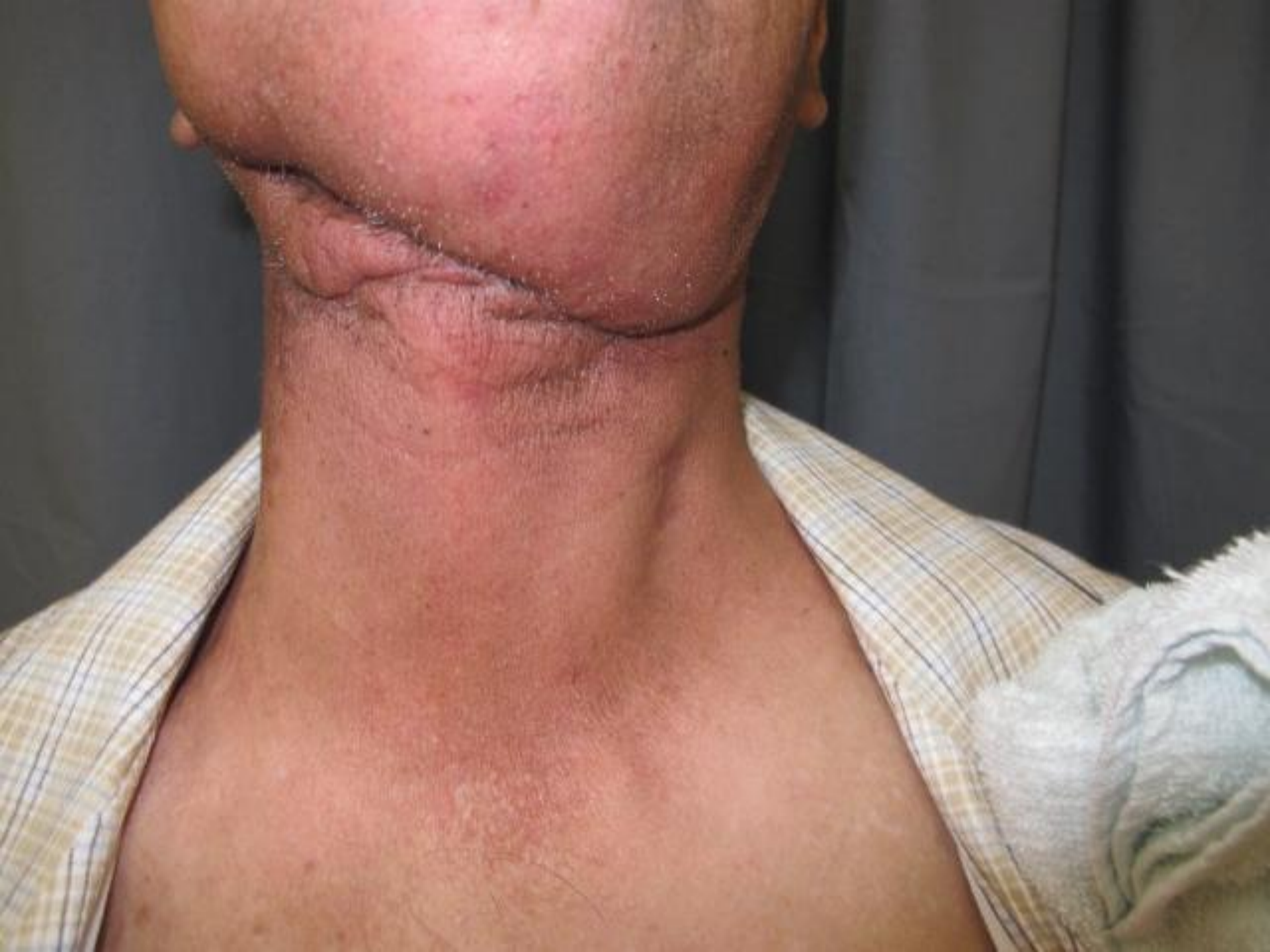Radiation Dermatitis



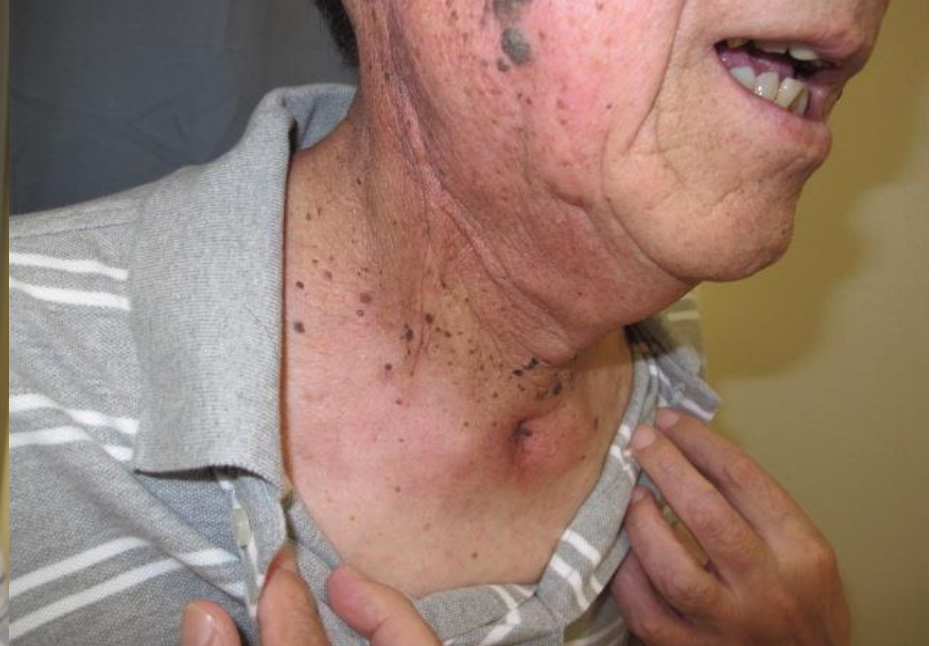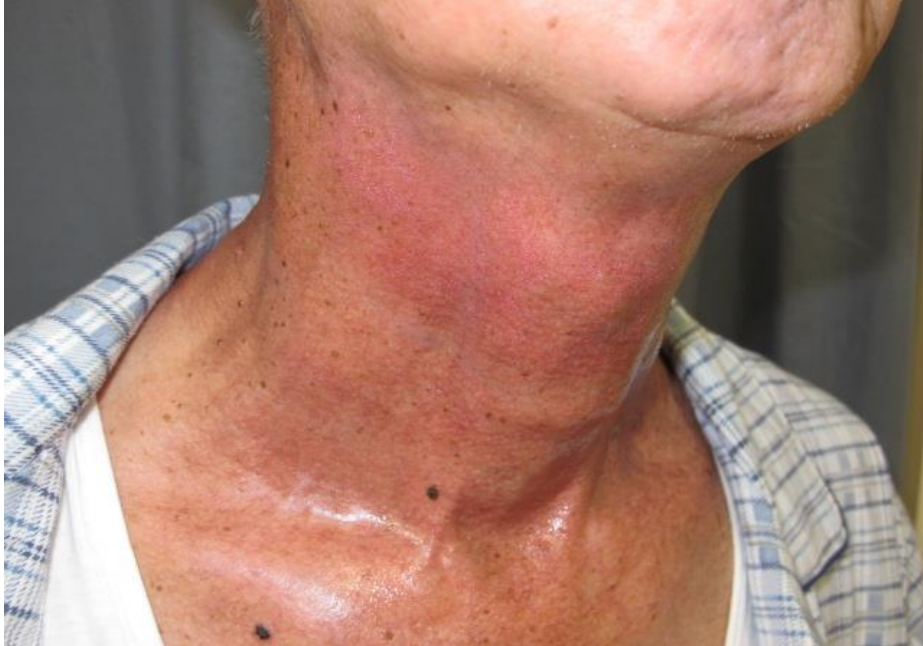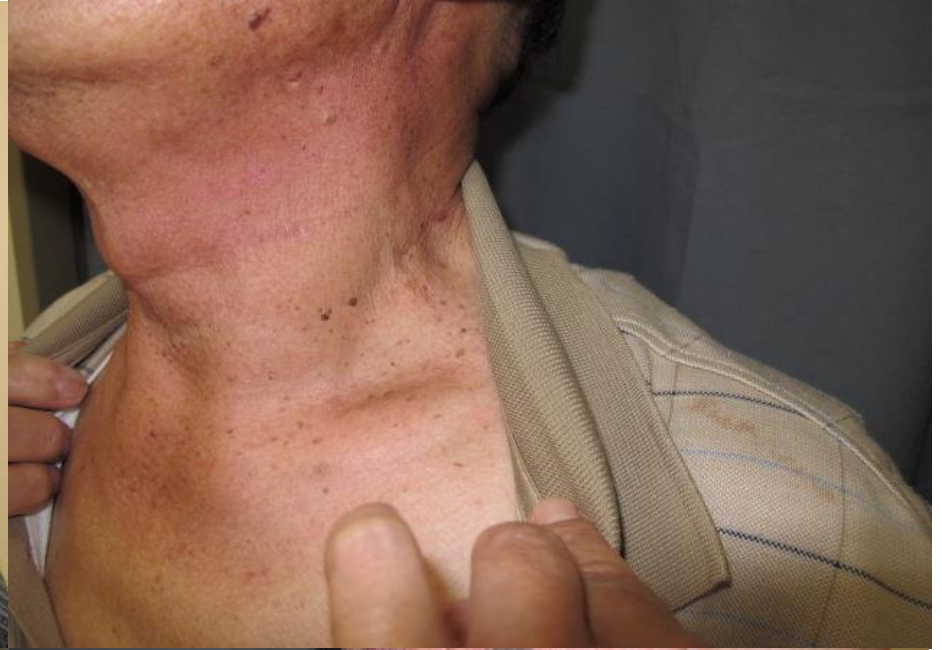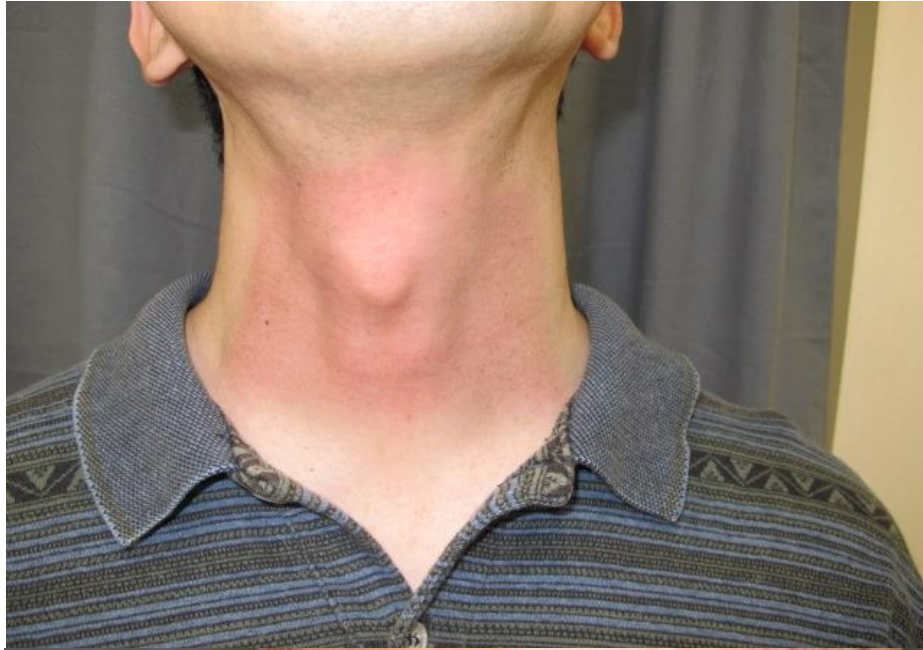Faint Erythema

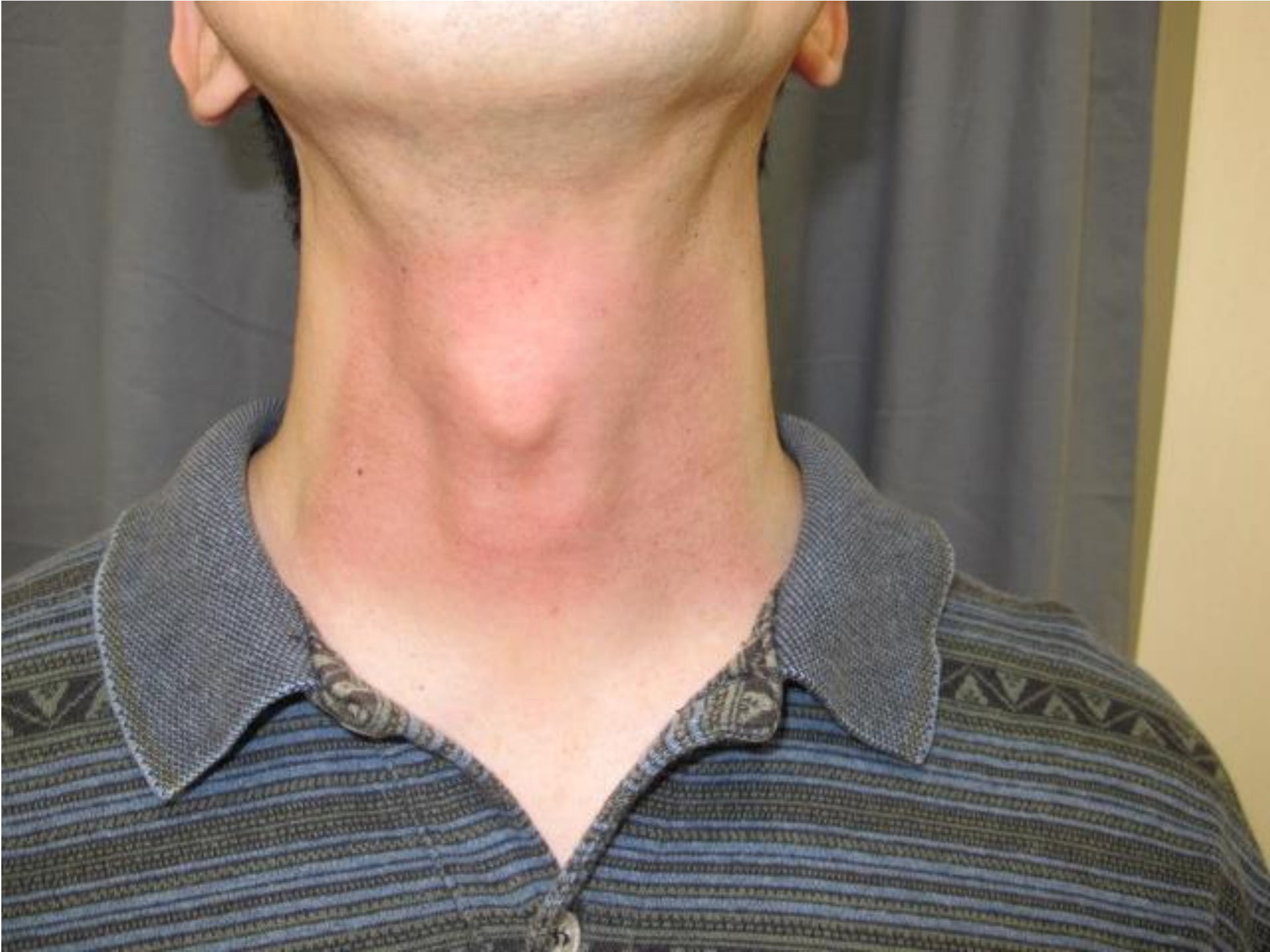


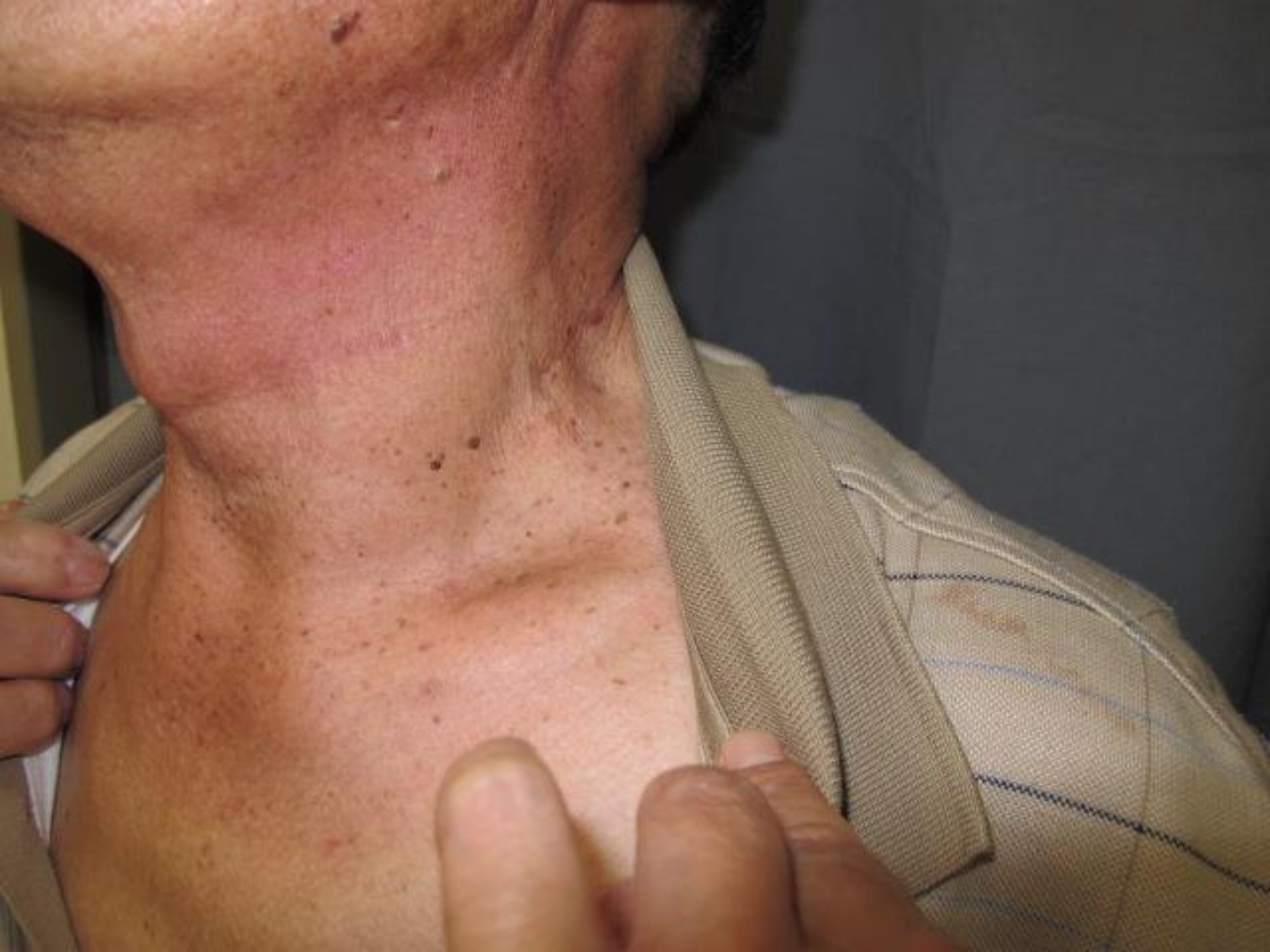


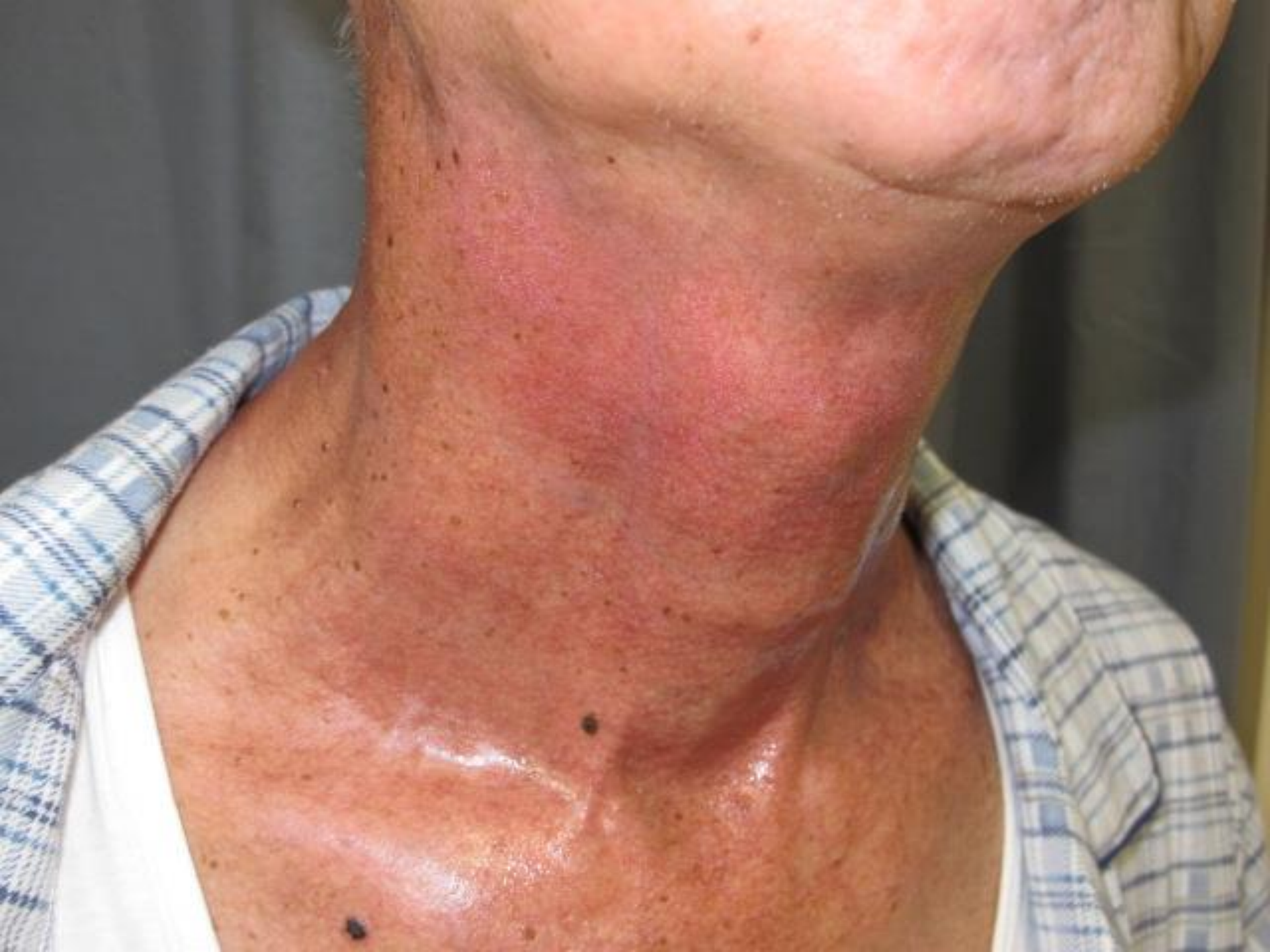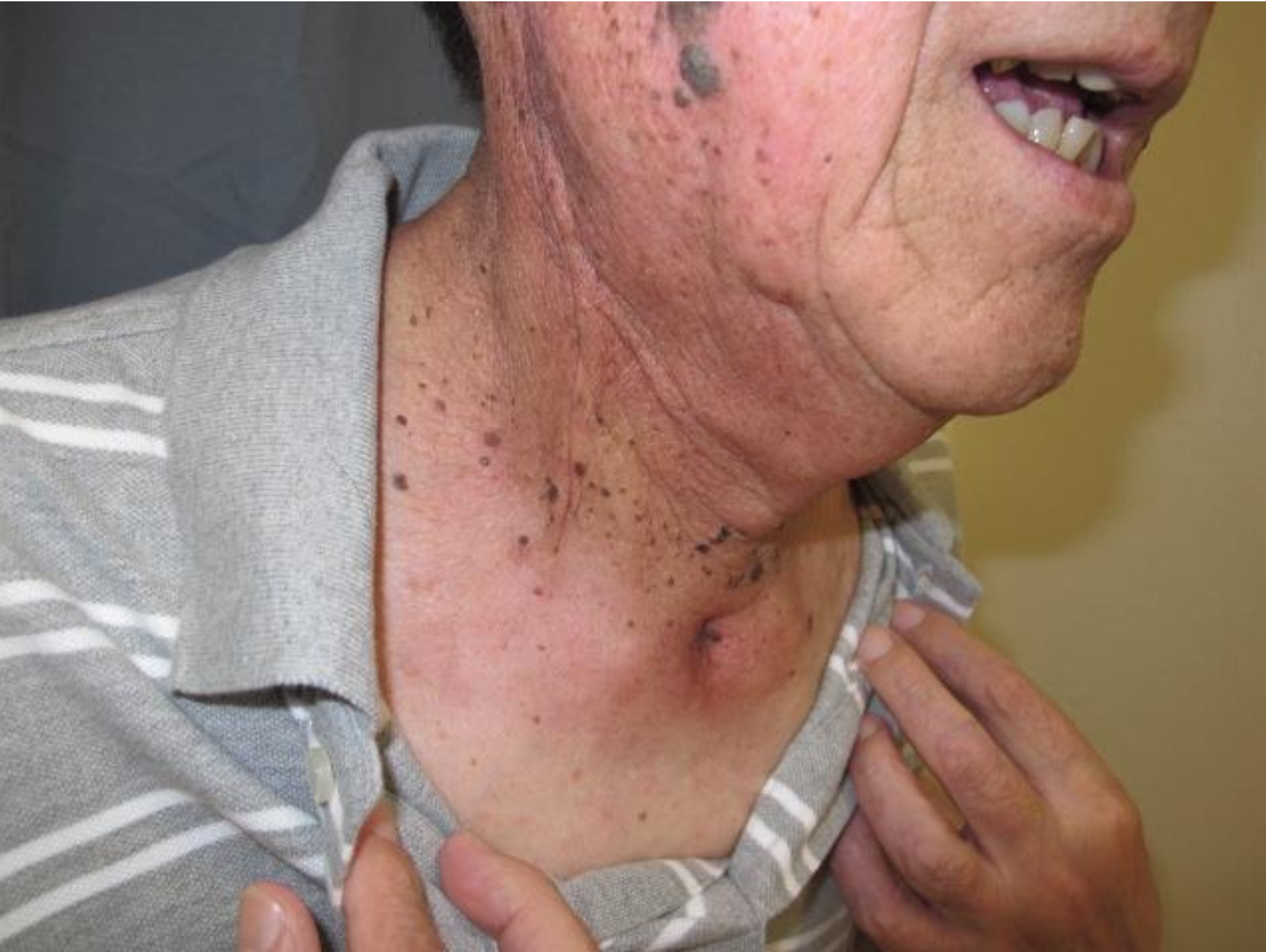Salmon pink erythema

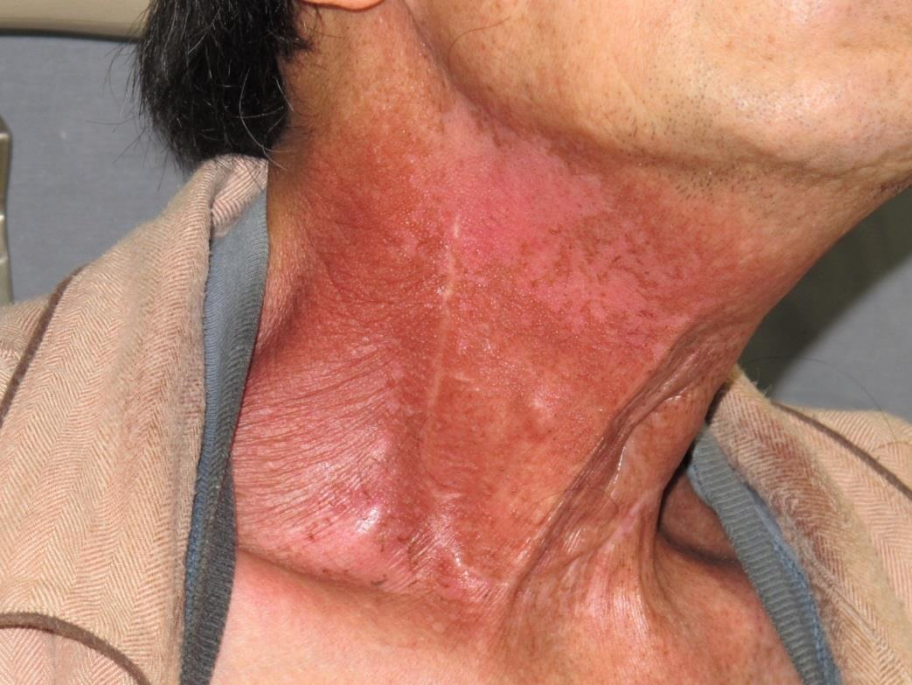
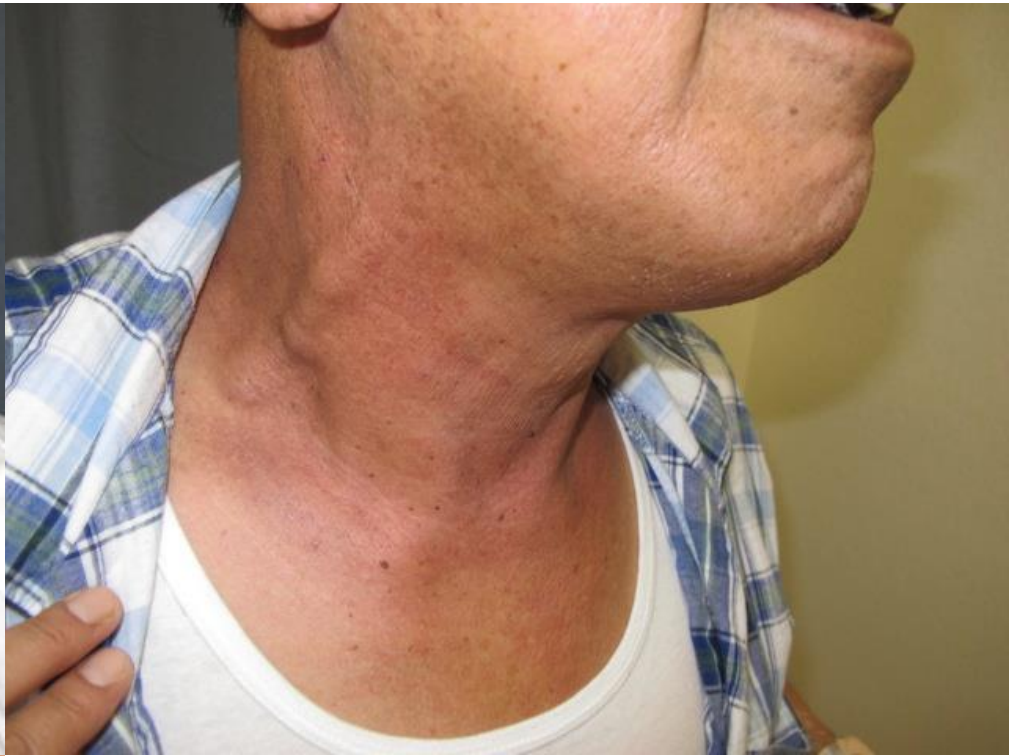
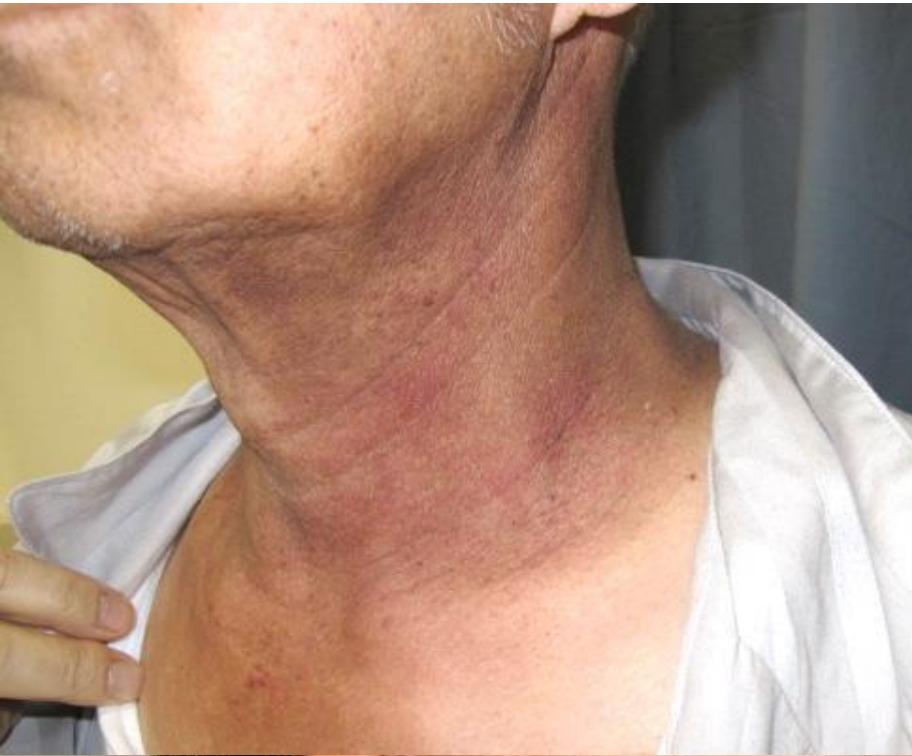




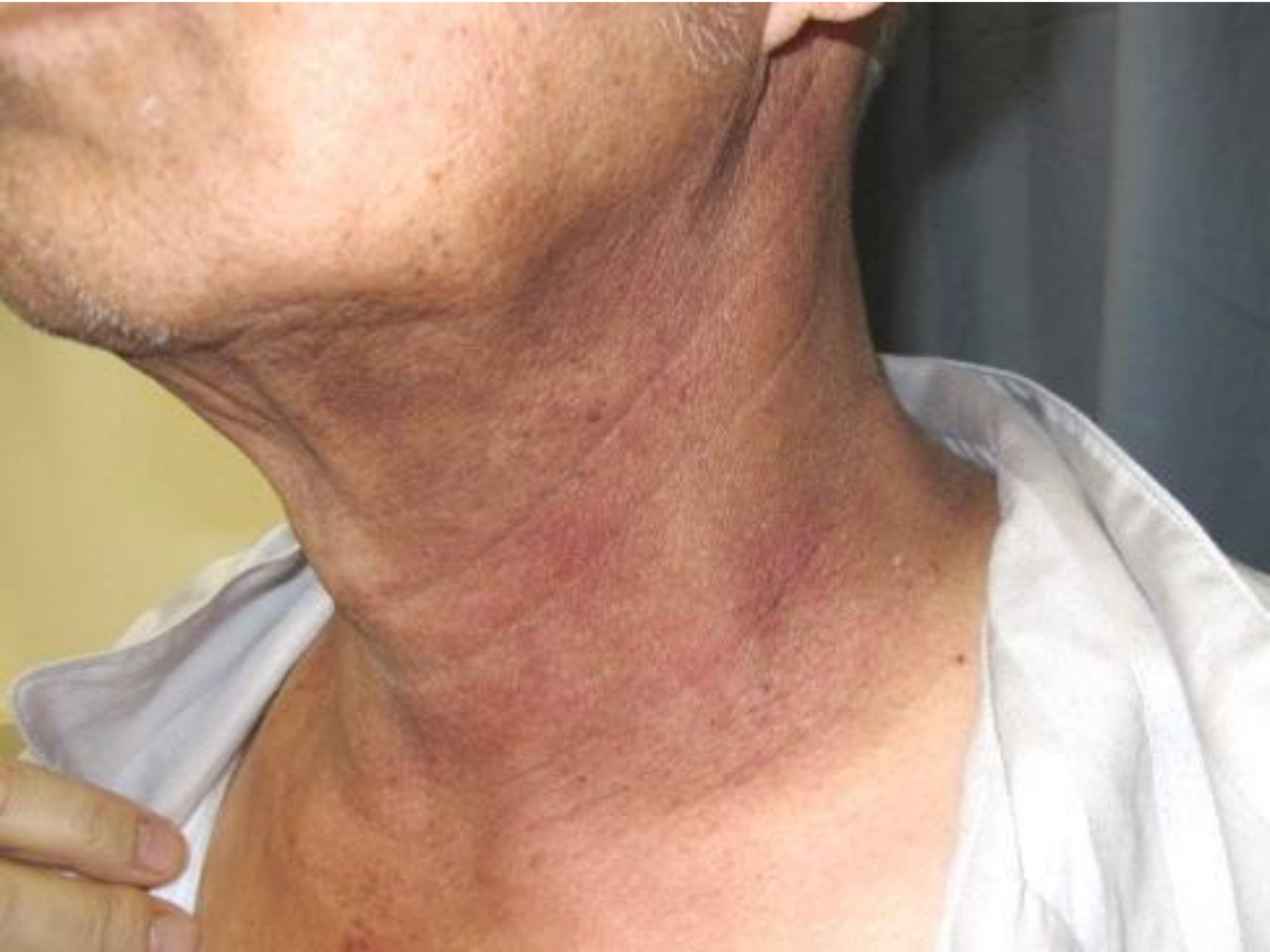


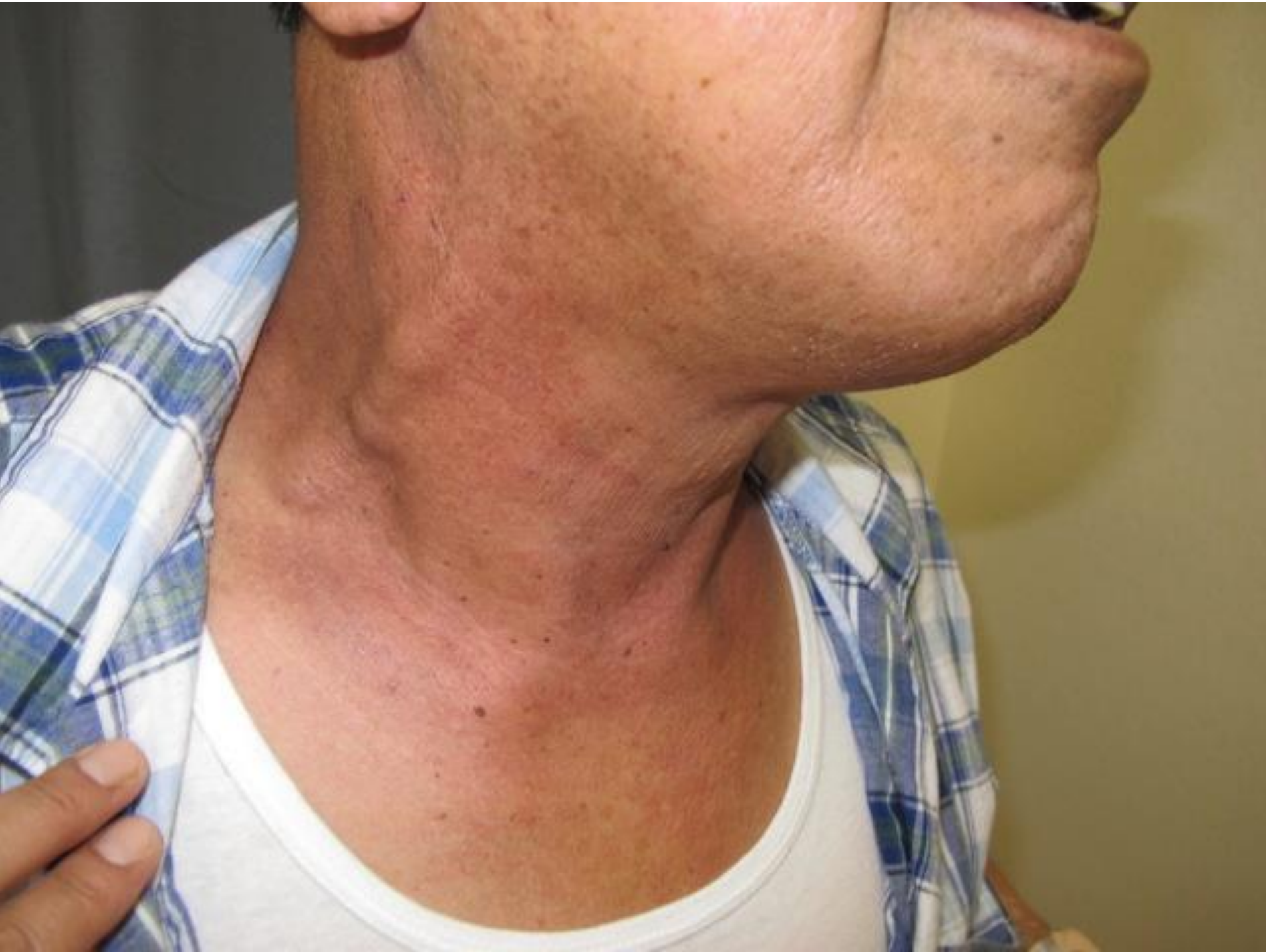

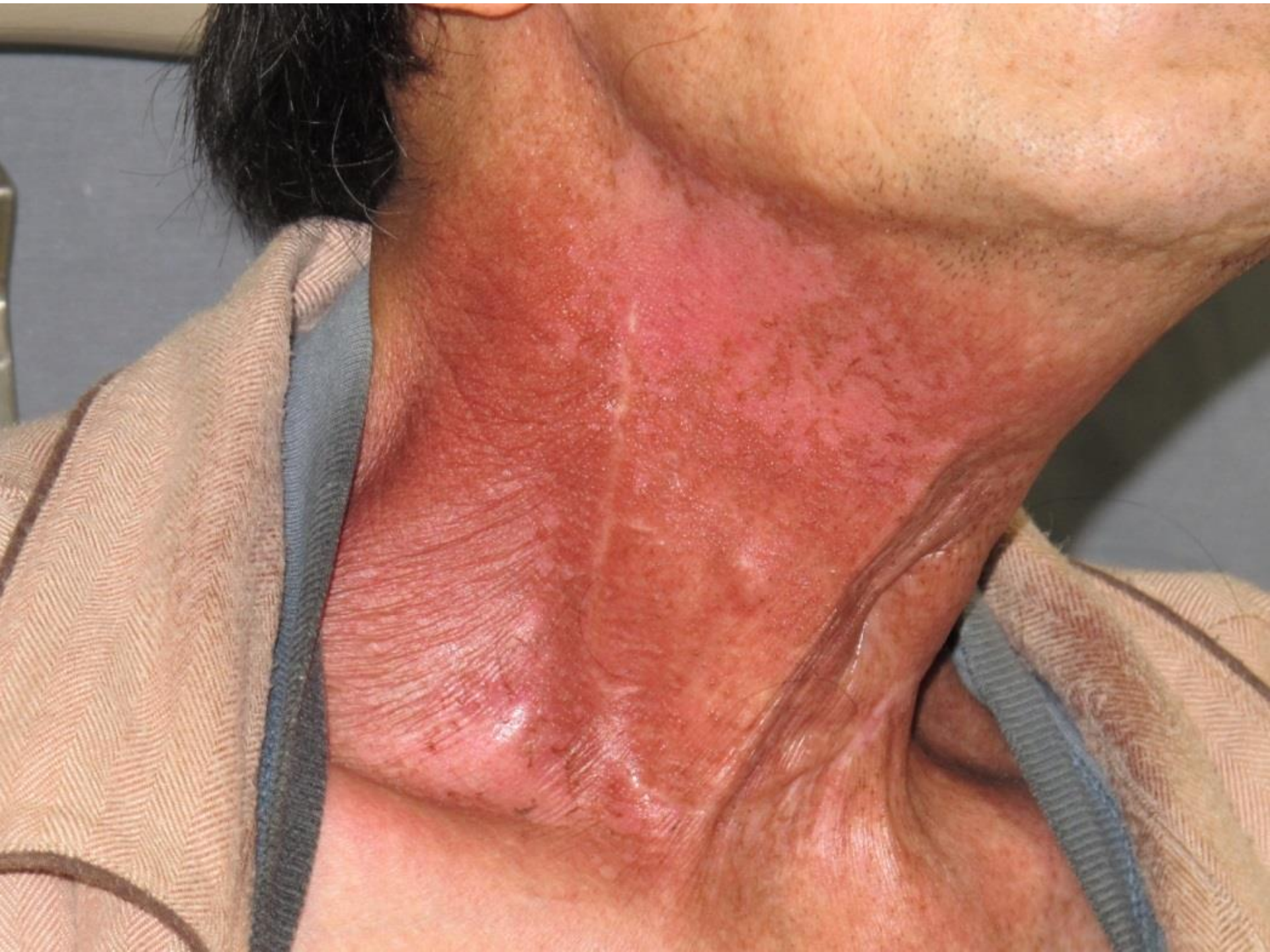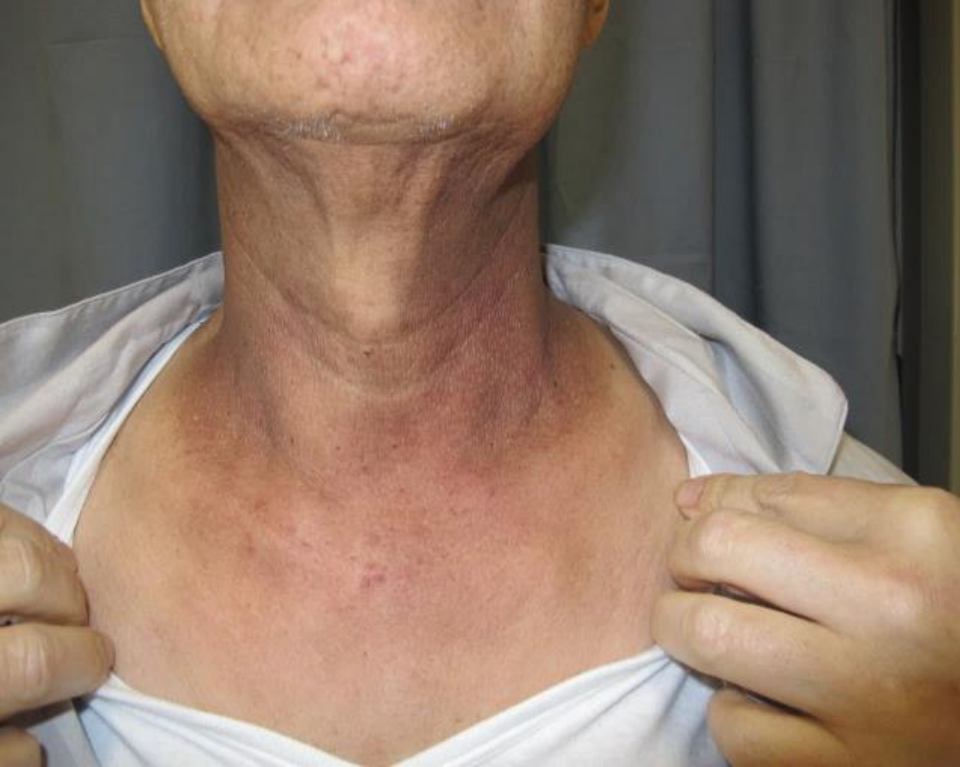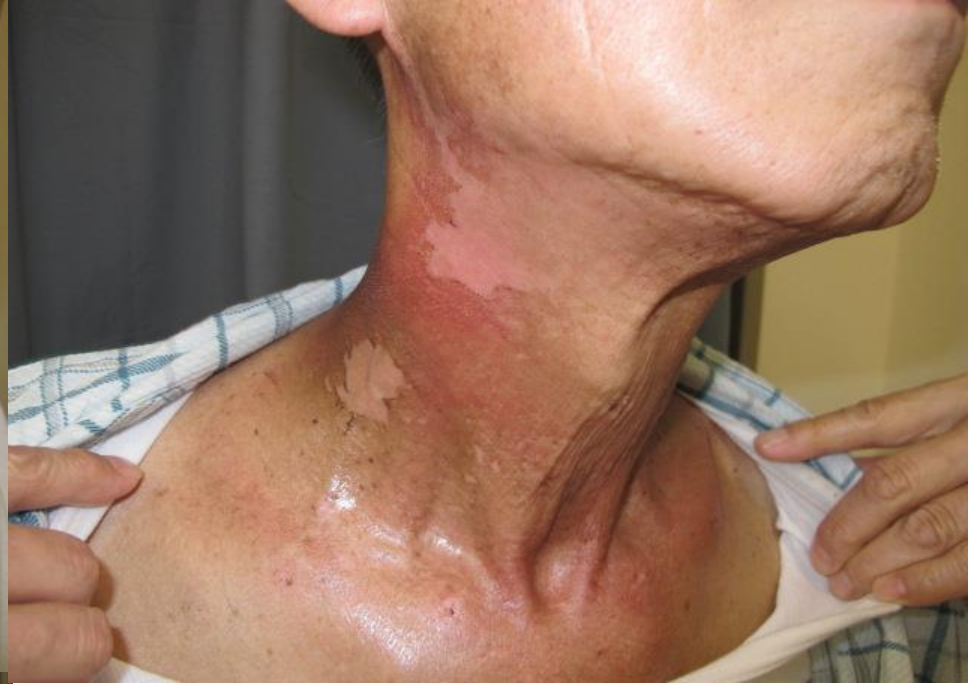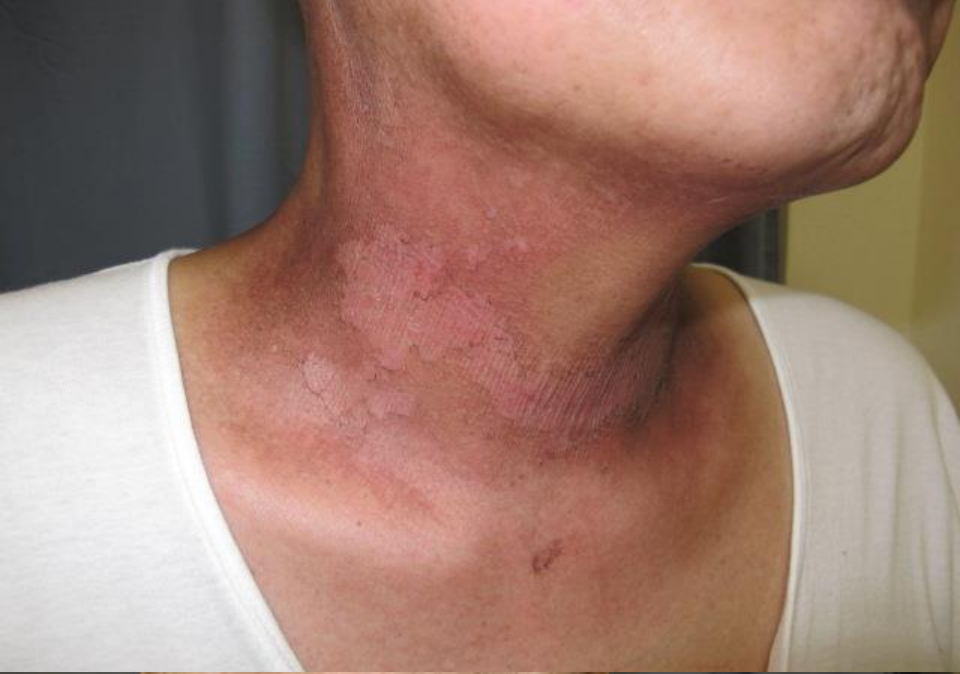Light brown erythema

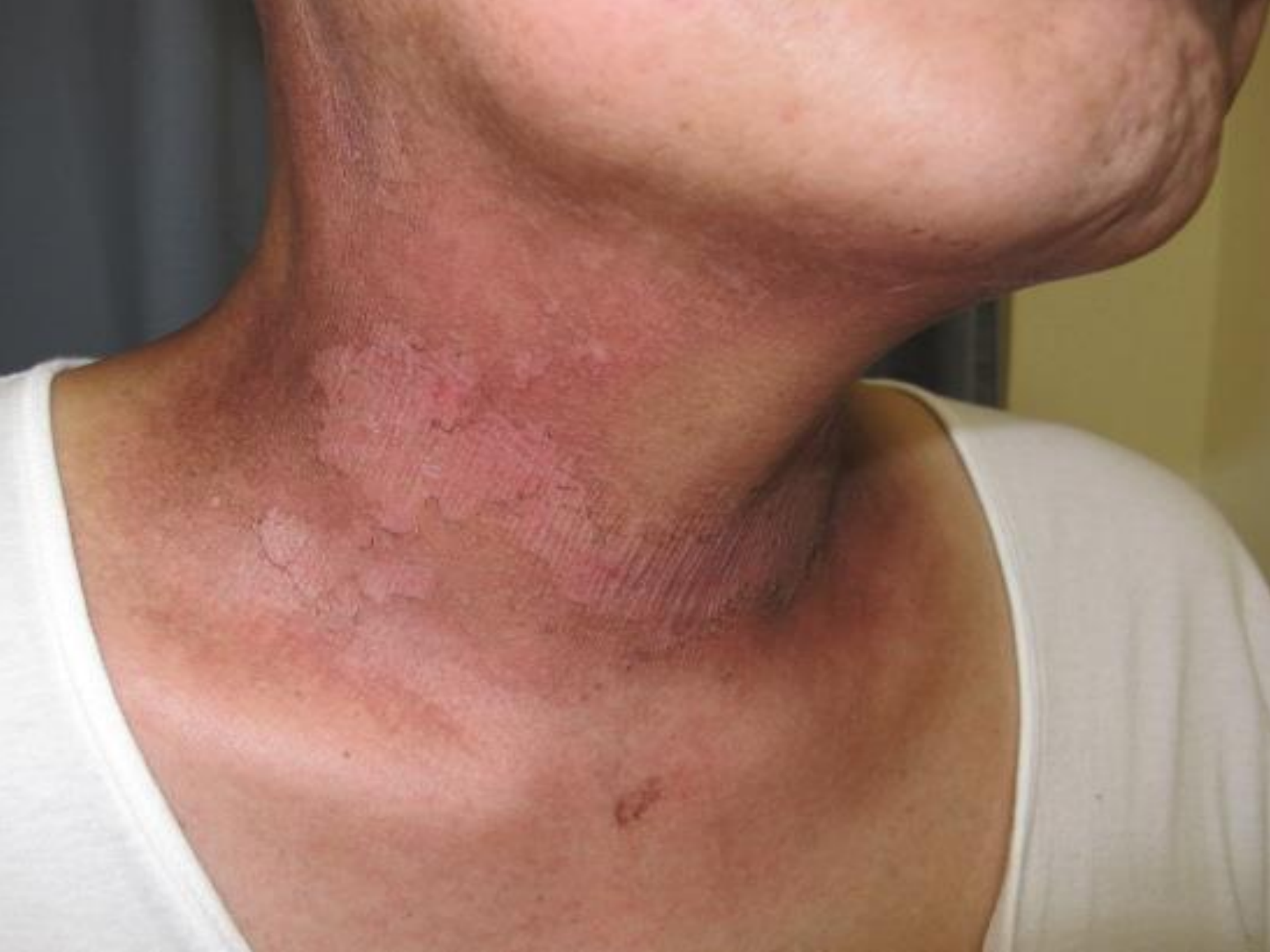


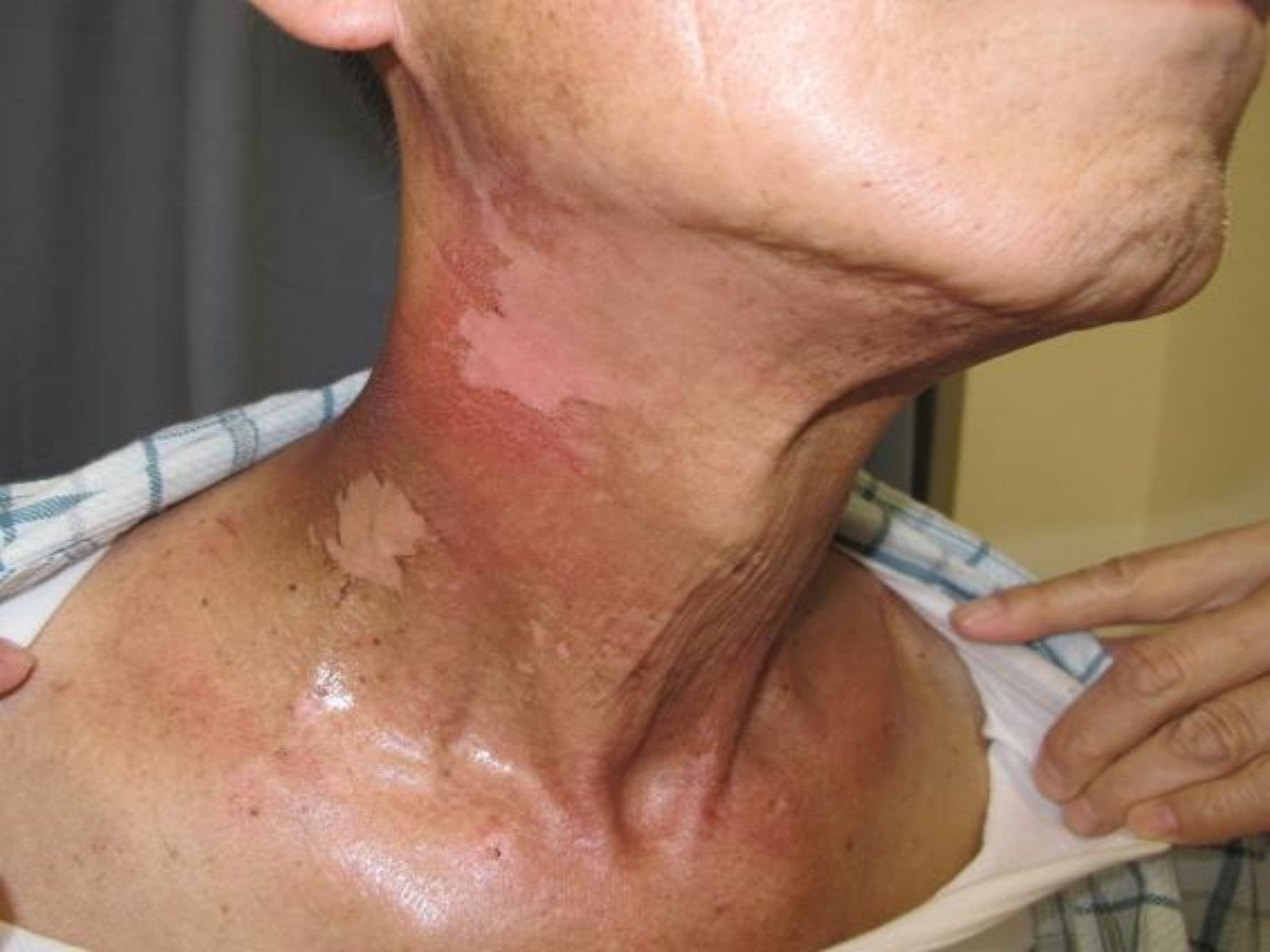


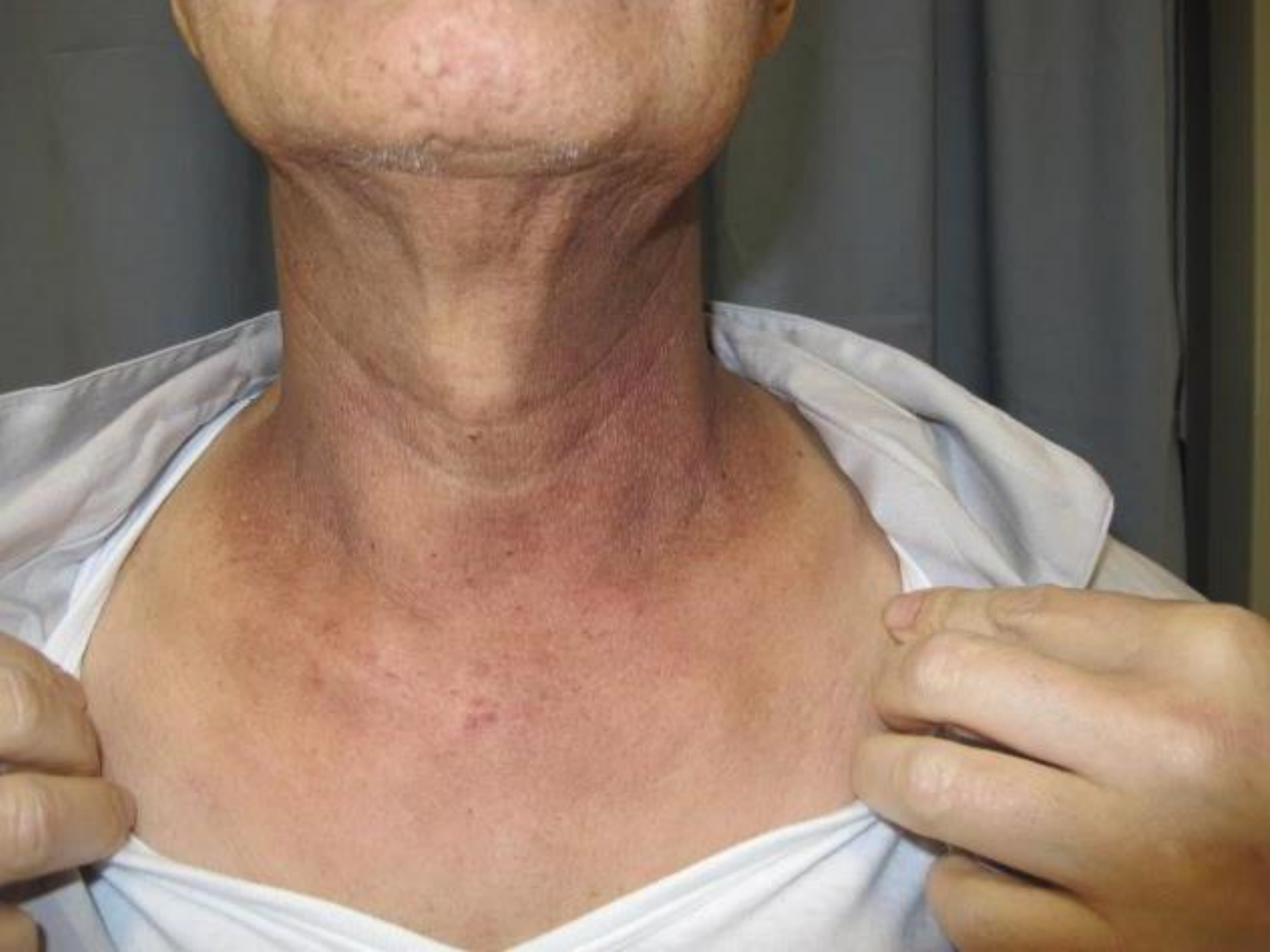

Dry desquamation

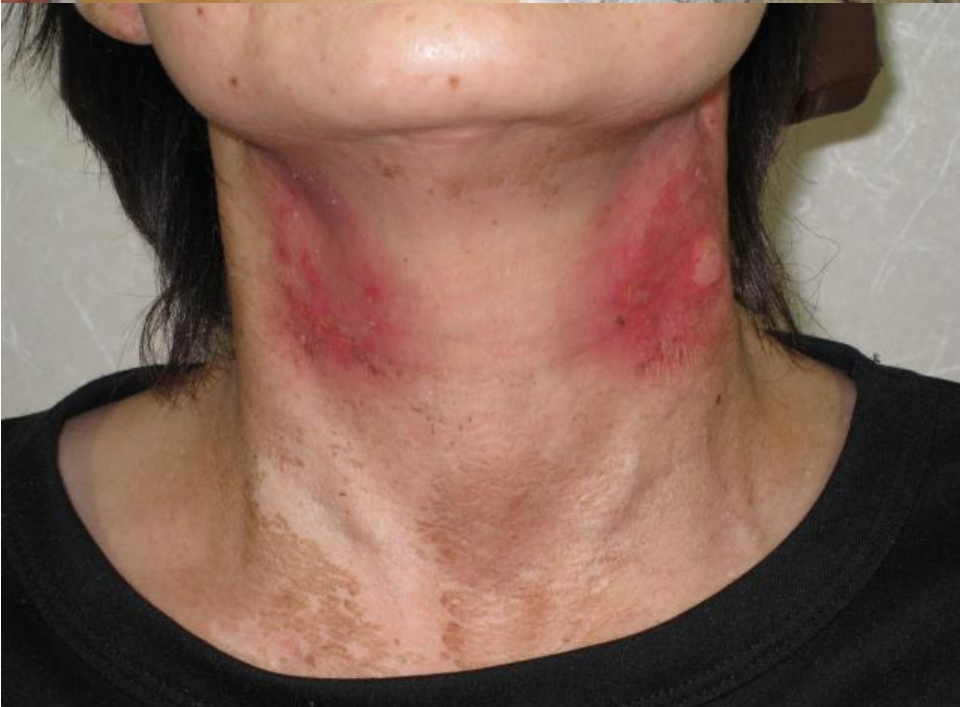
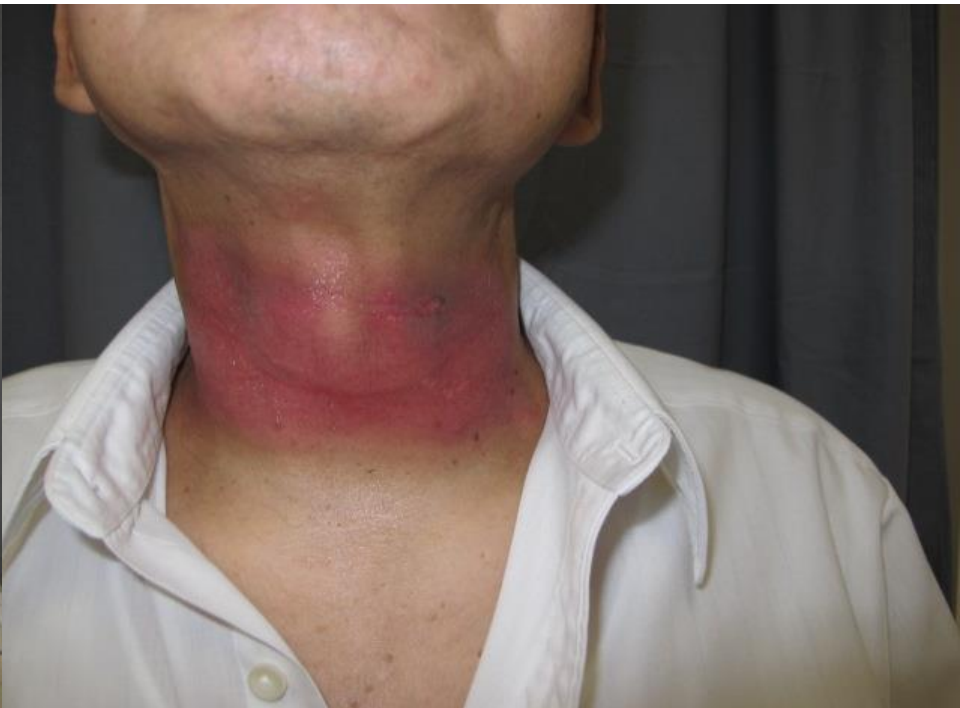
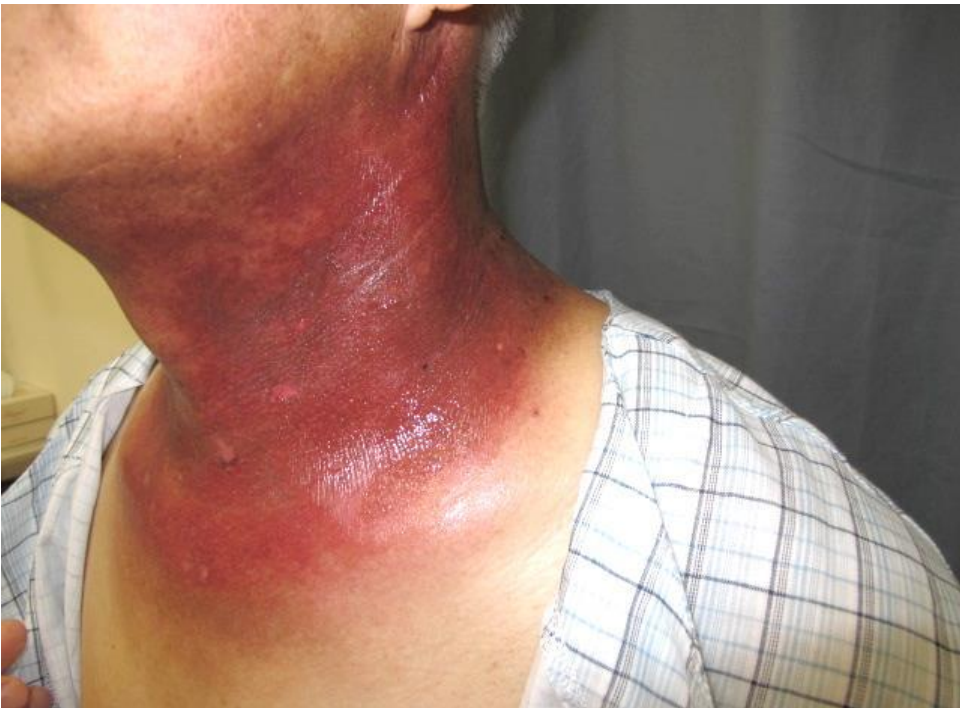



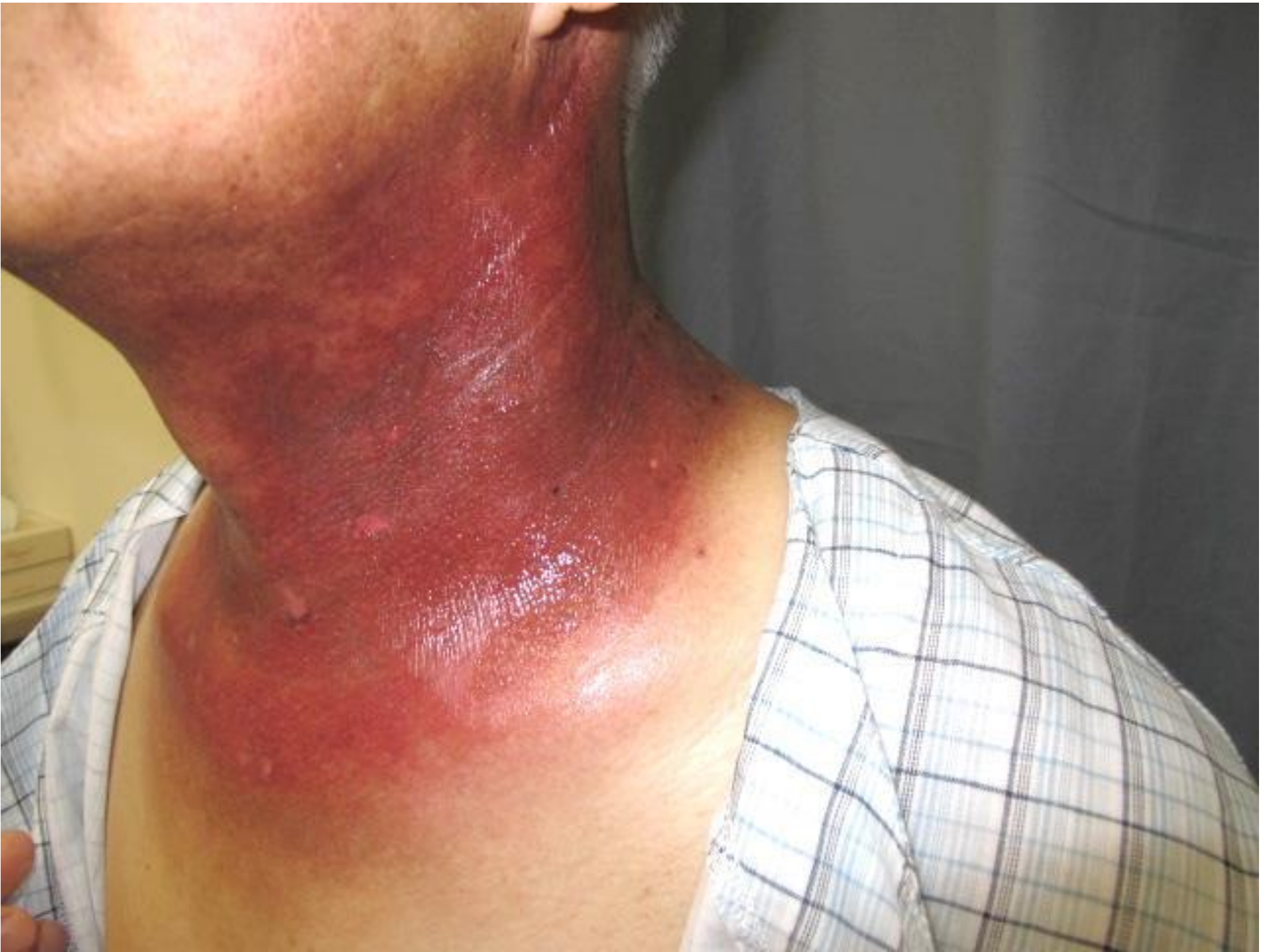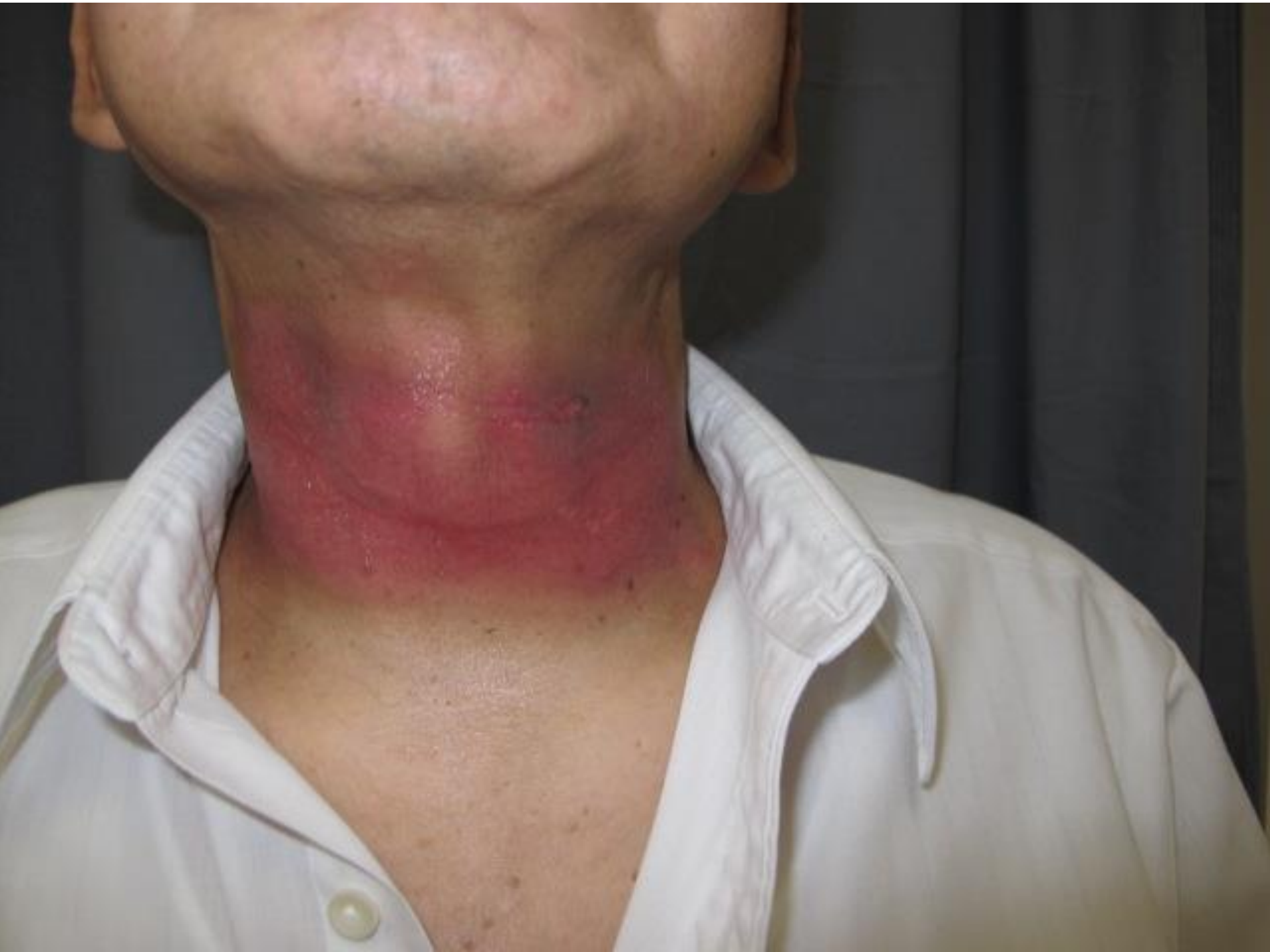Gr.2

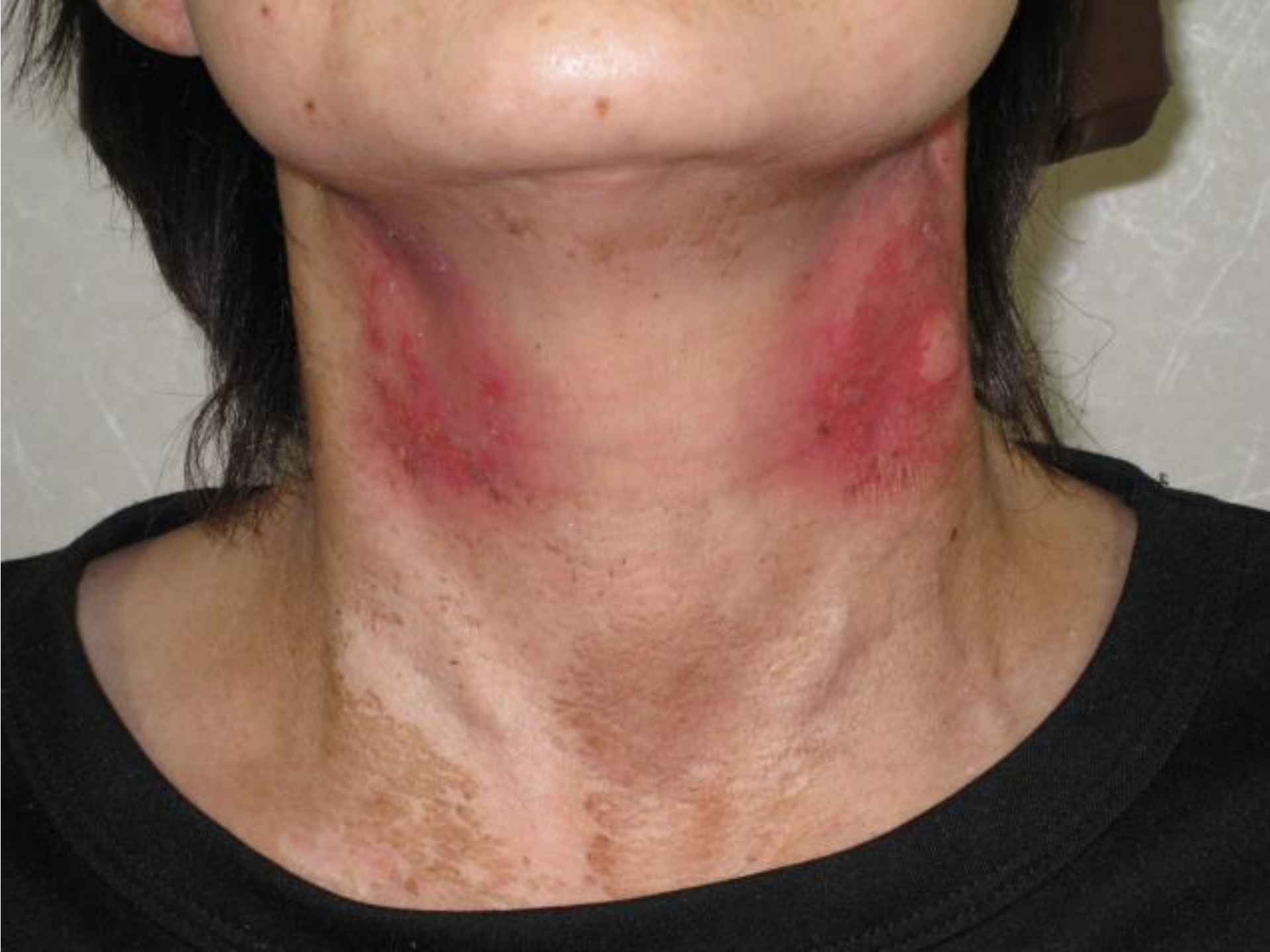Radiation Dermatitis



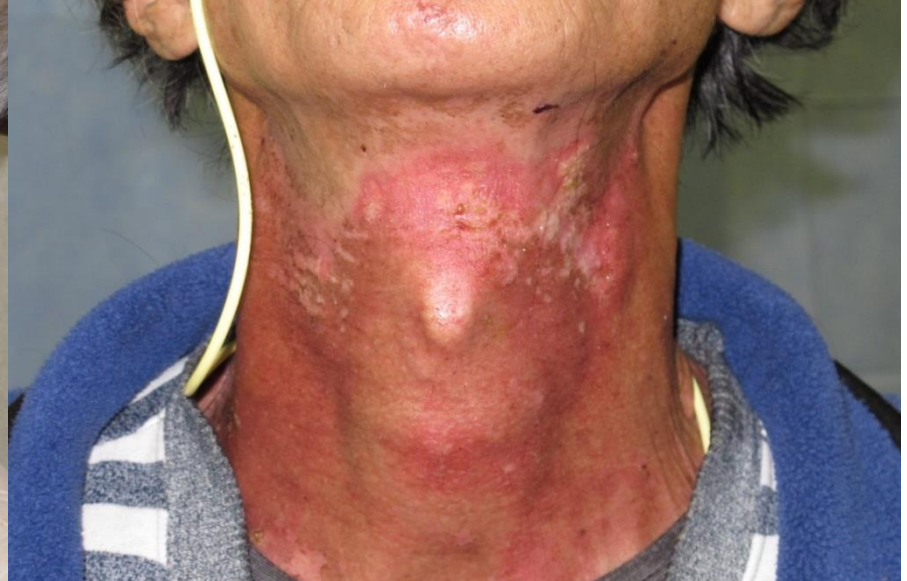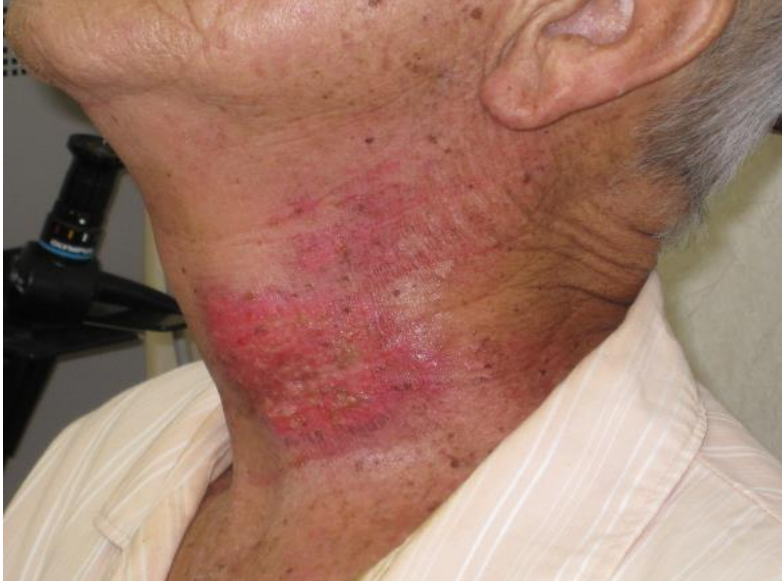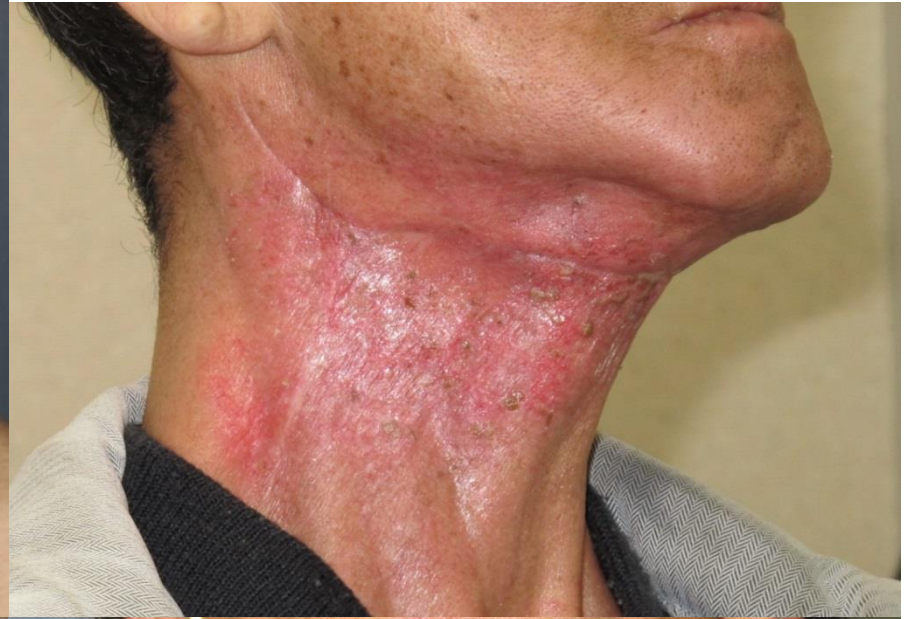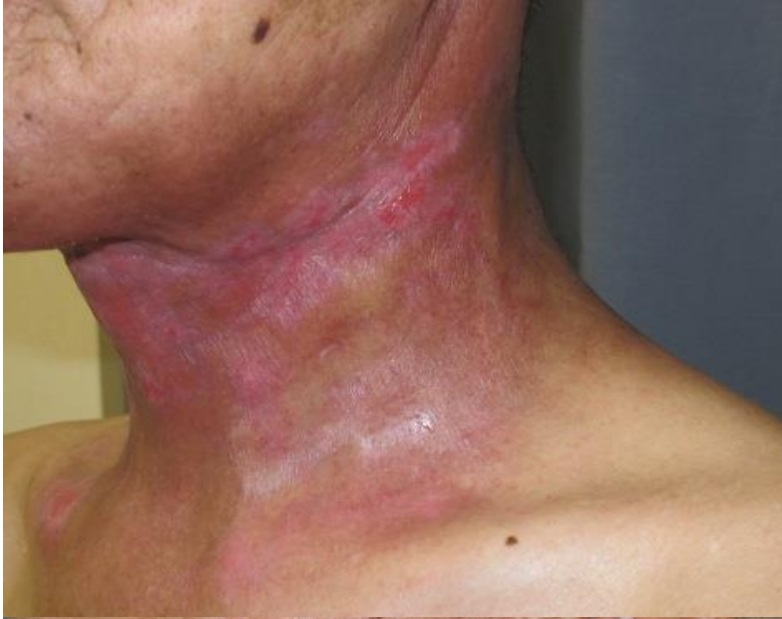**Moderate to brisk
erythema**

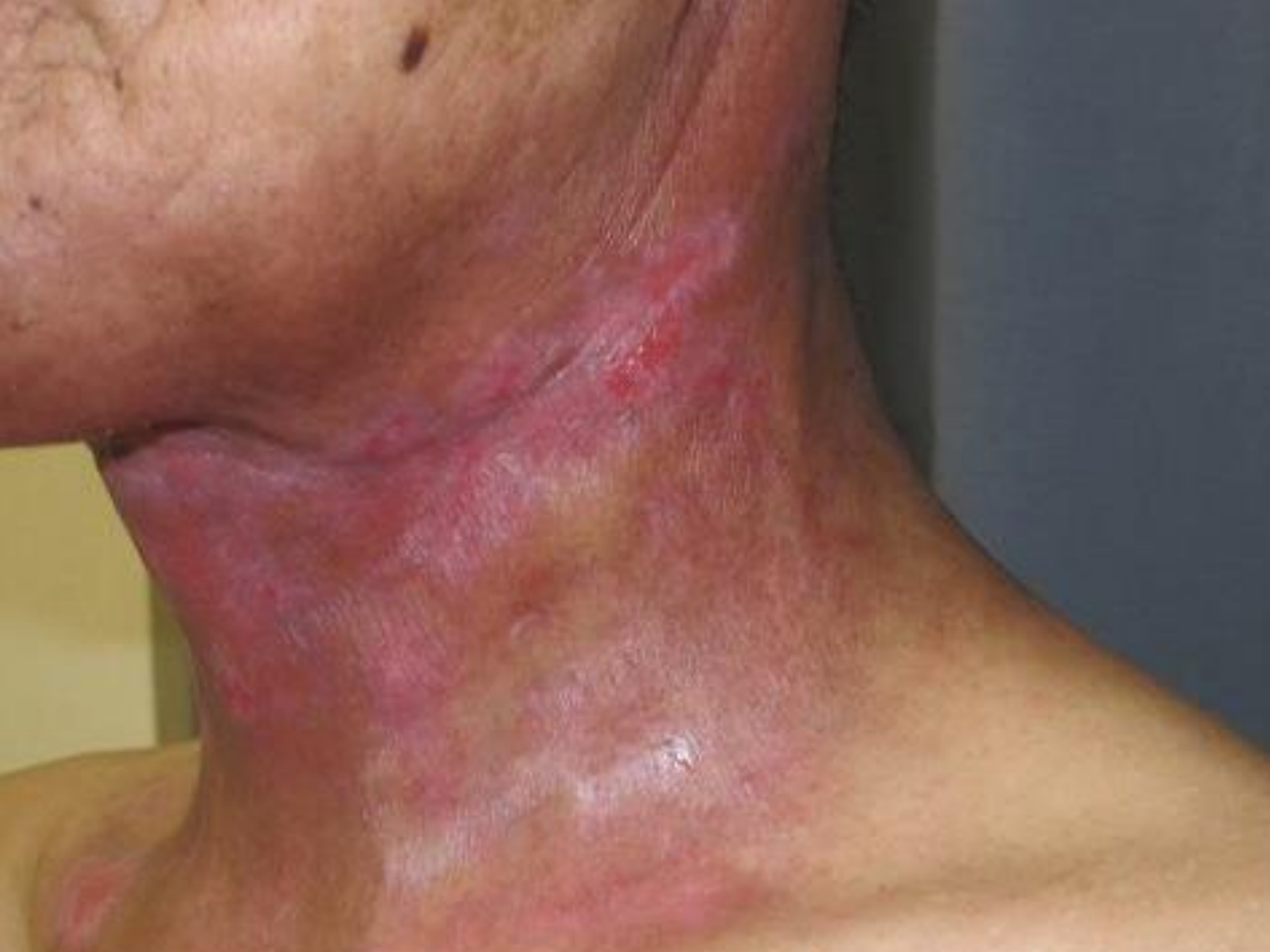


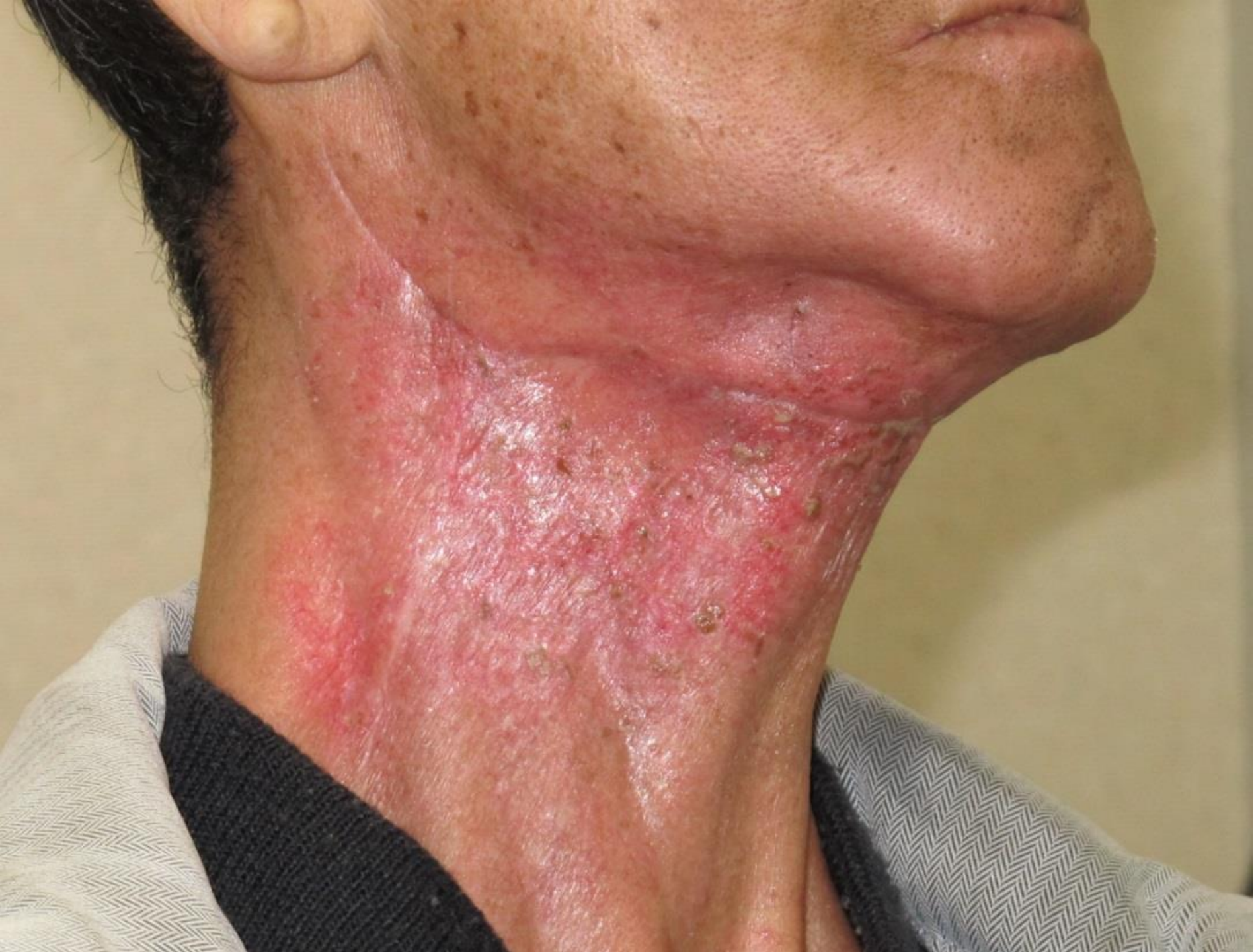


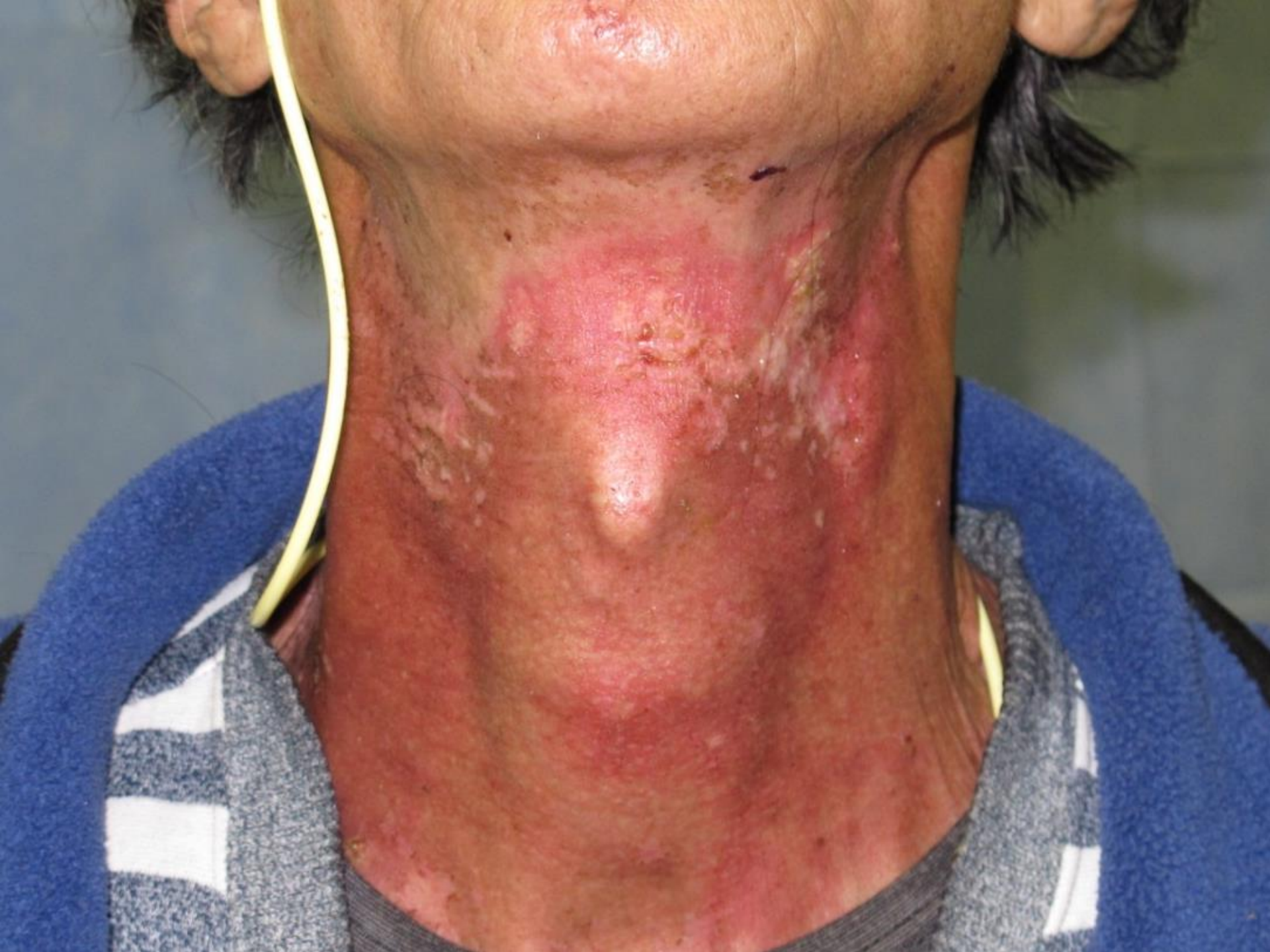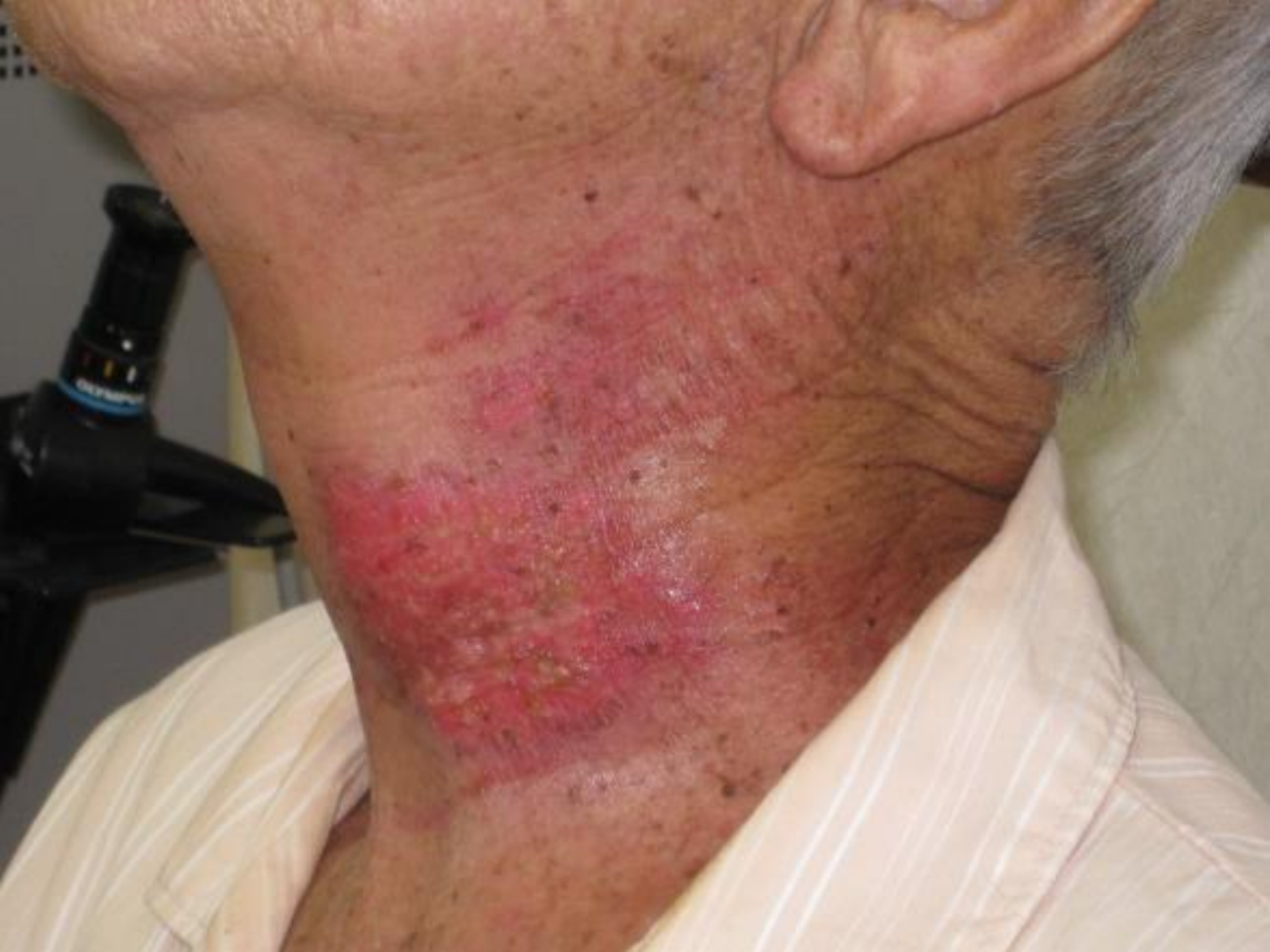Moist desquamation, mostly confined to skin folds and creases





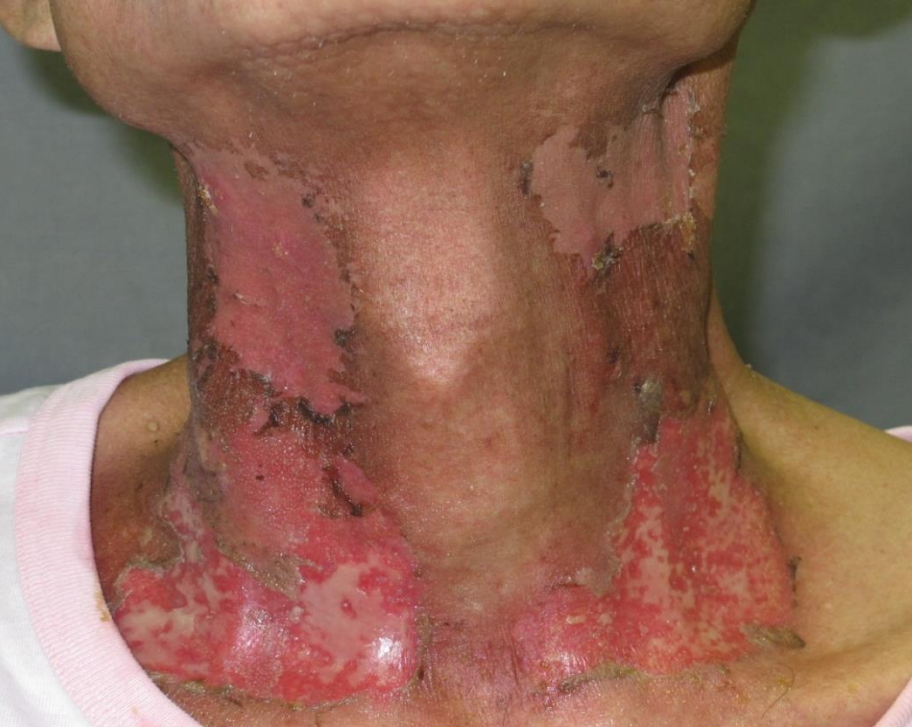
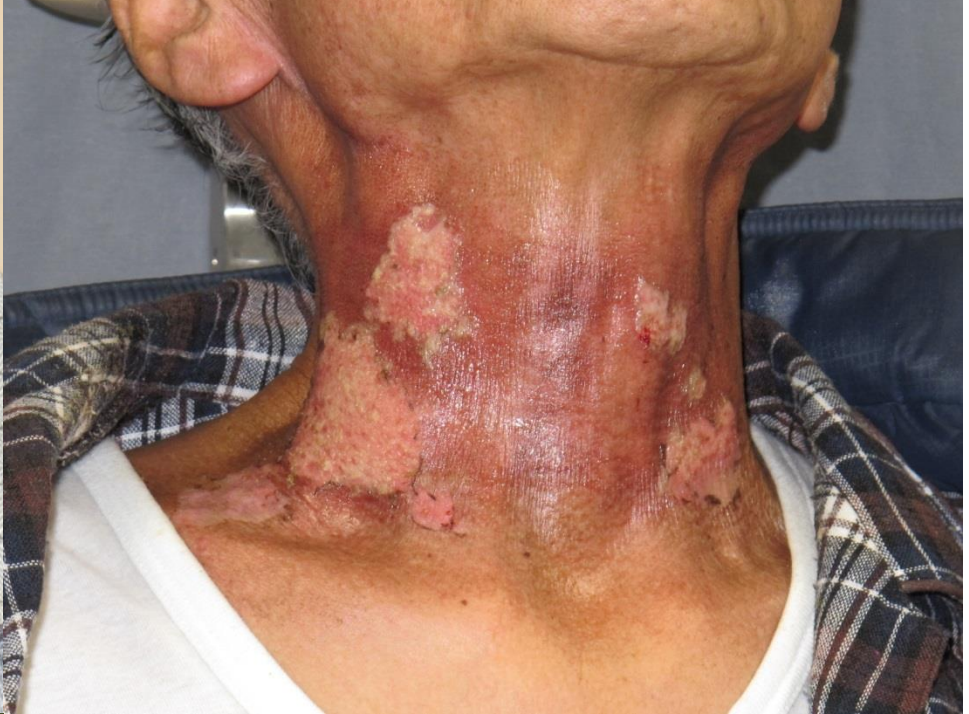
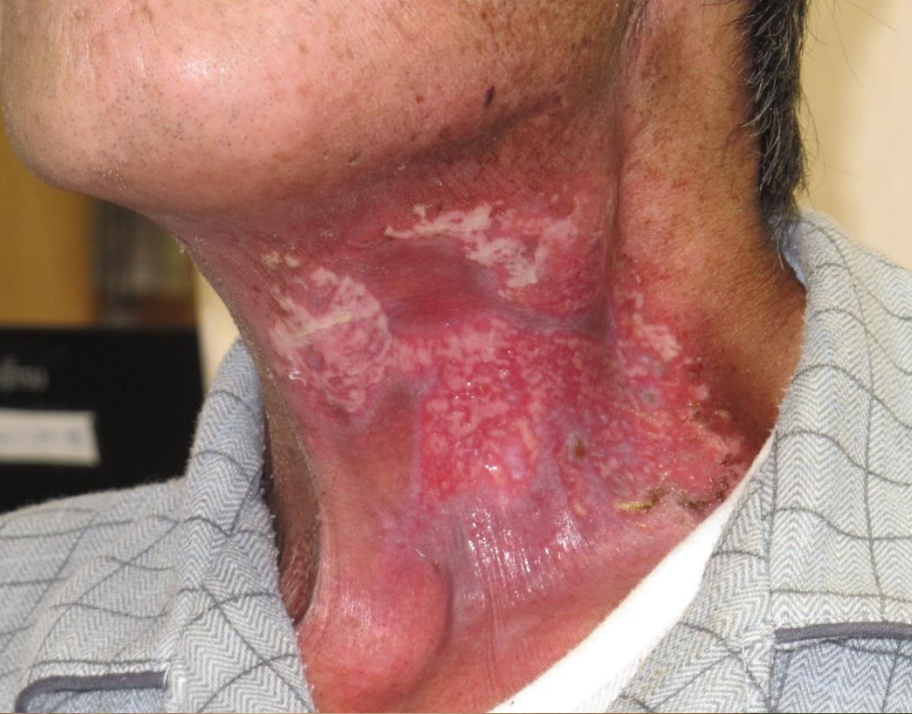



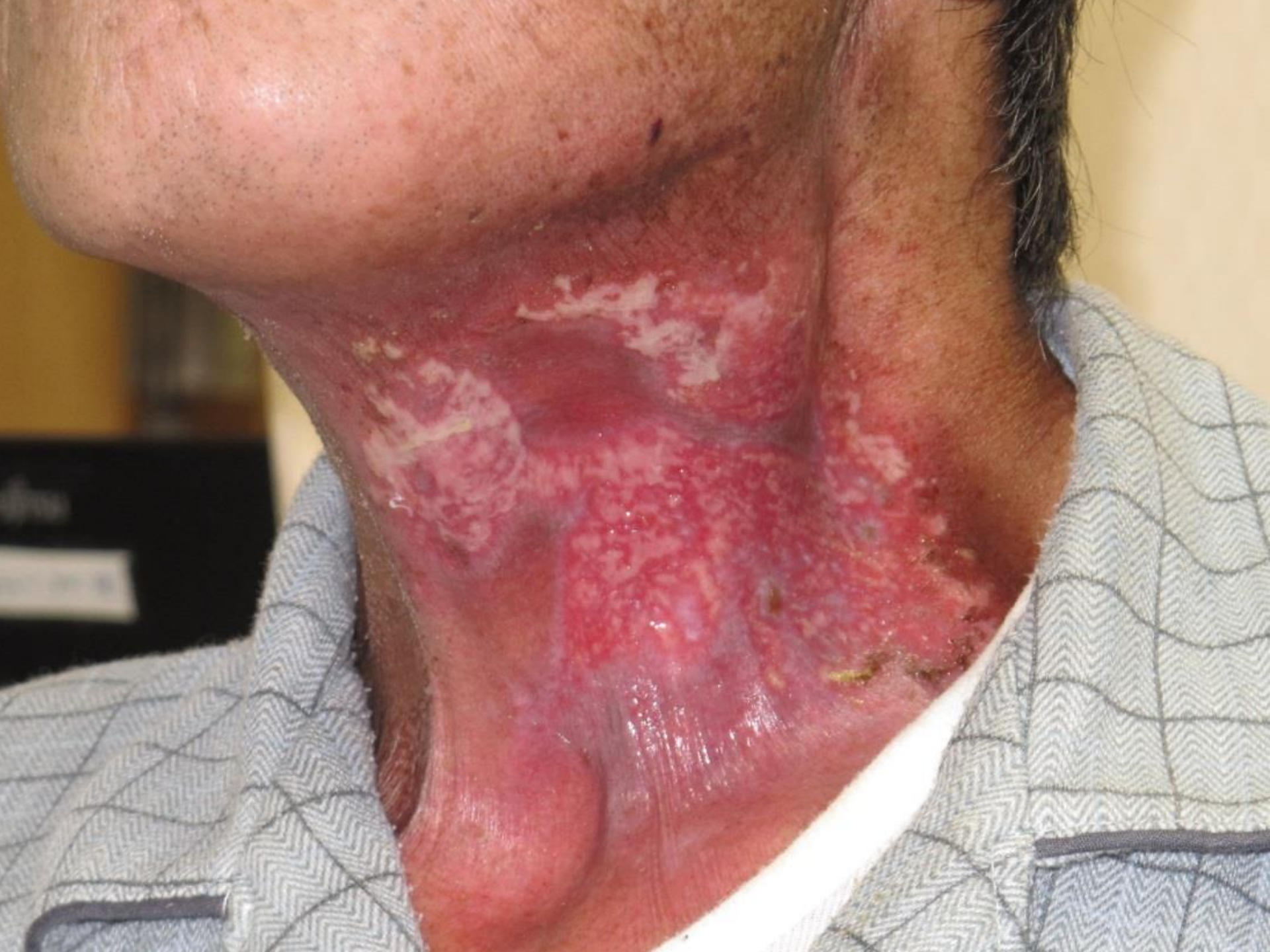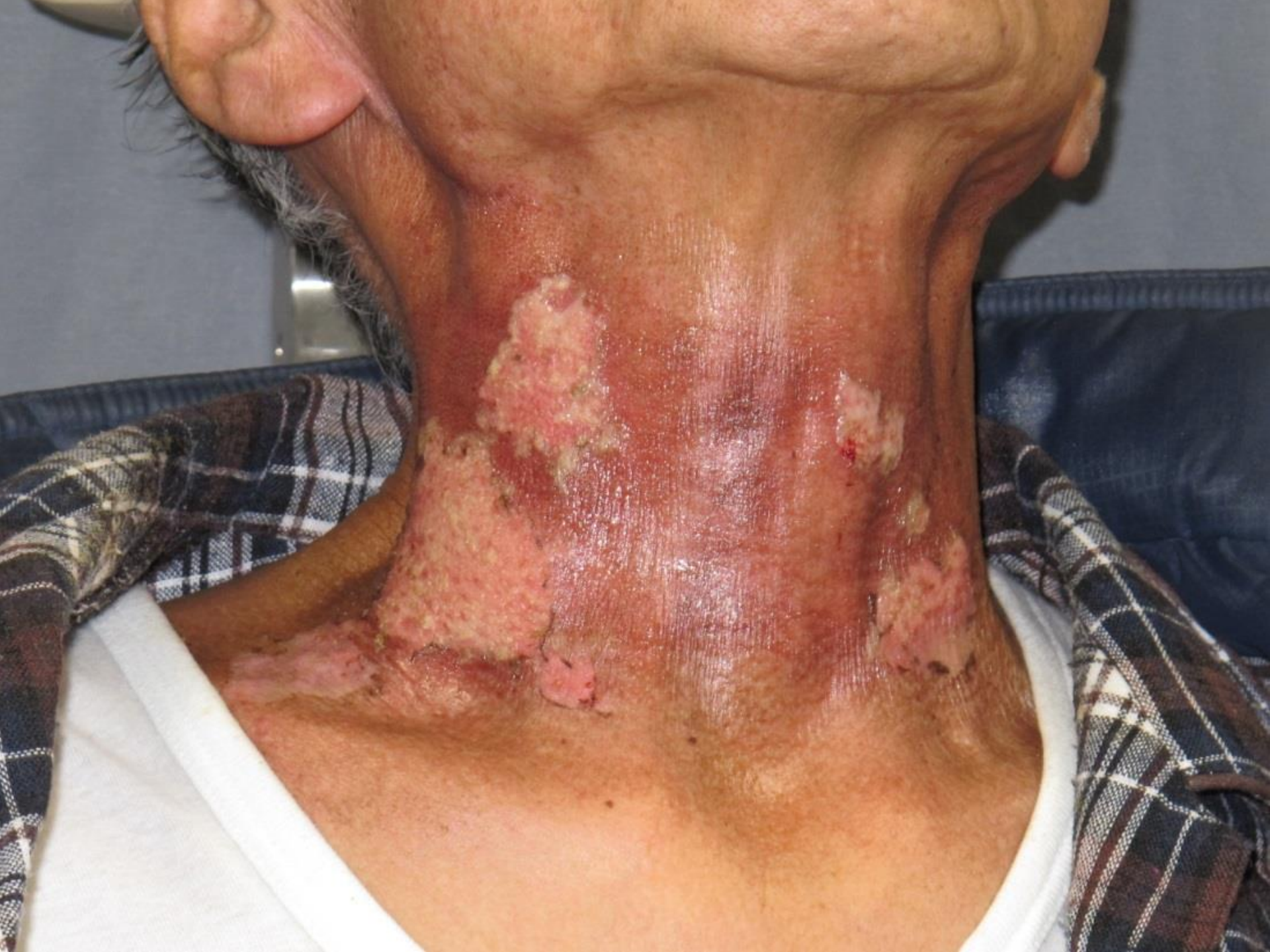Gr.3

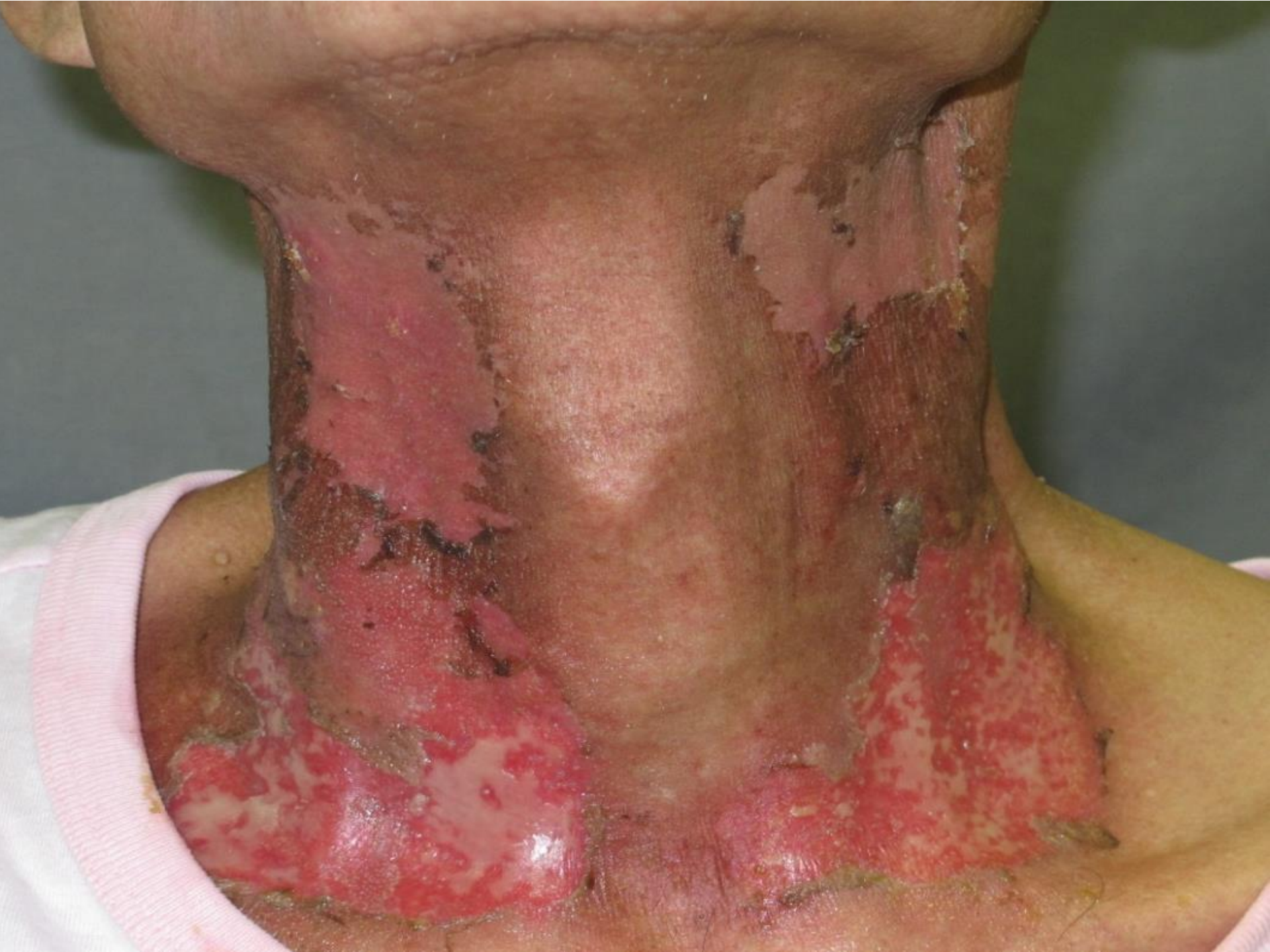Radiation Dermatitis

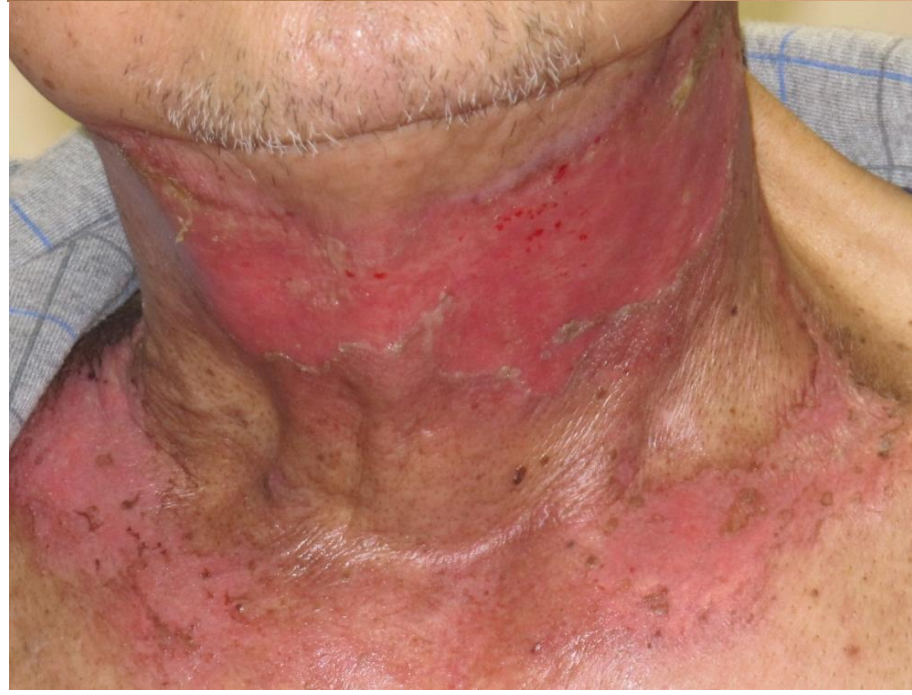
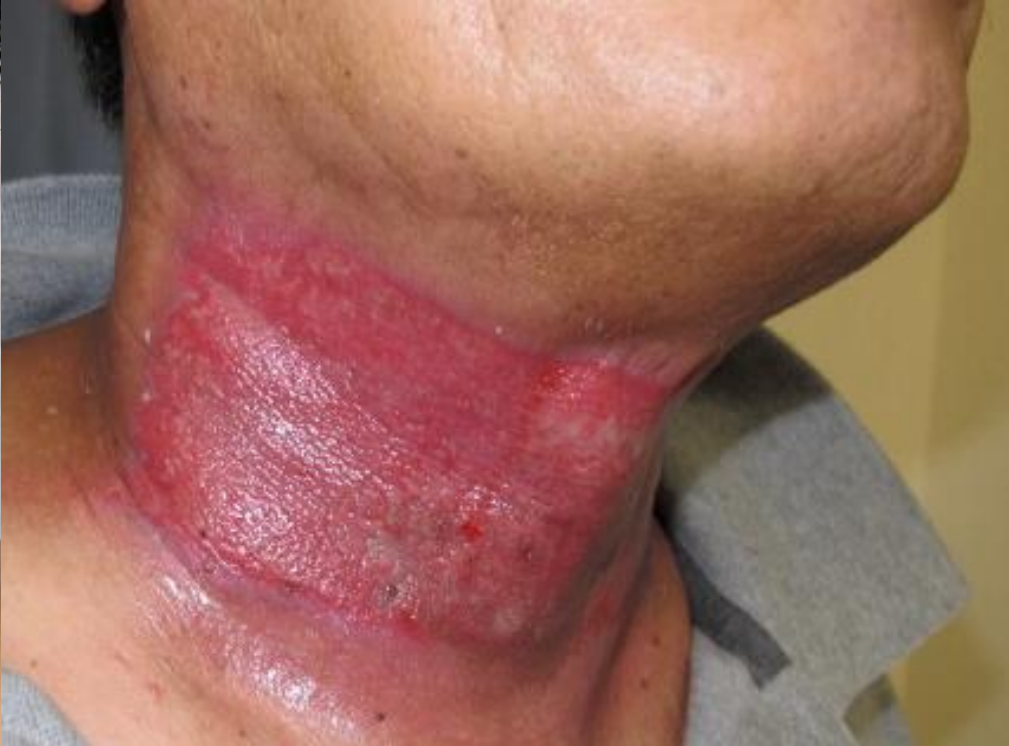
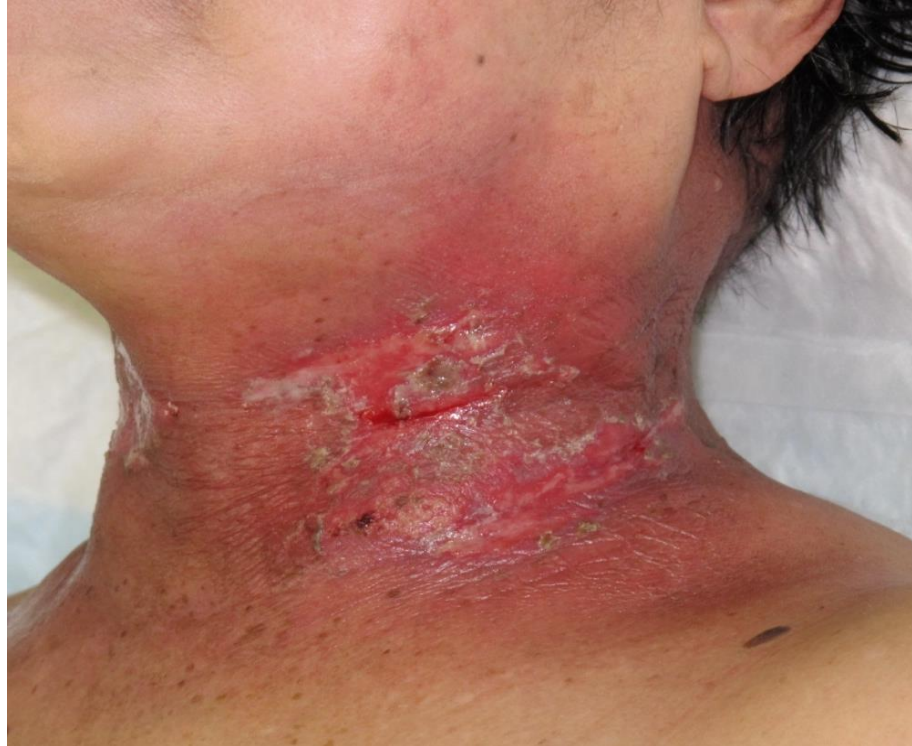**Moist desquamation
in areas
other than skin folds**

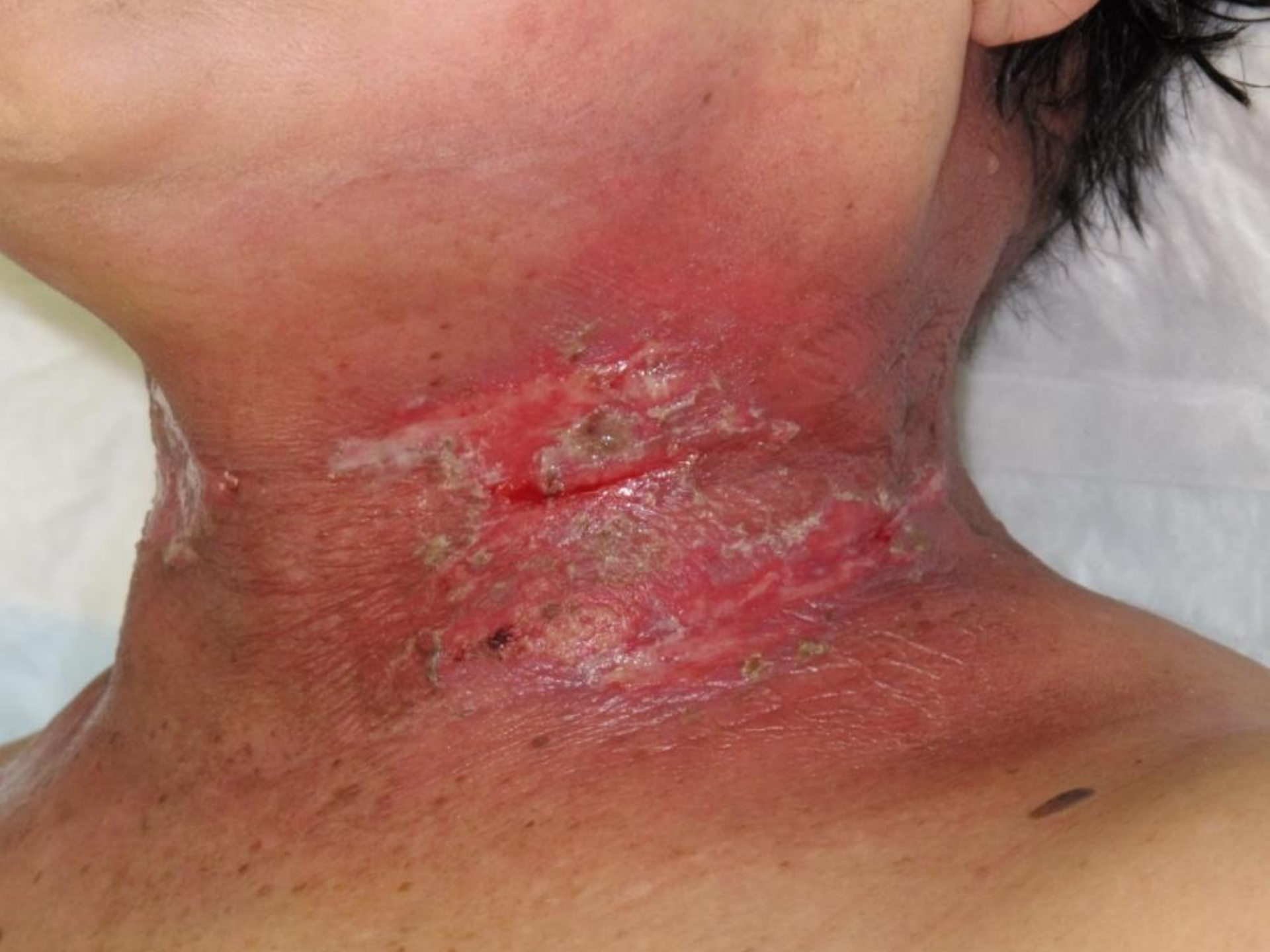


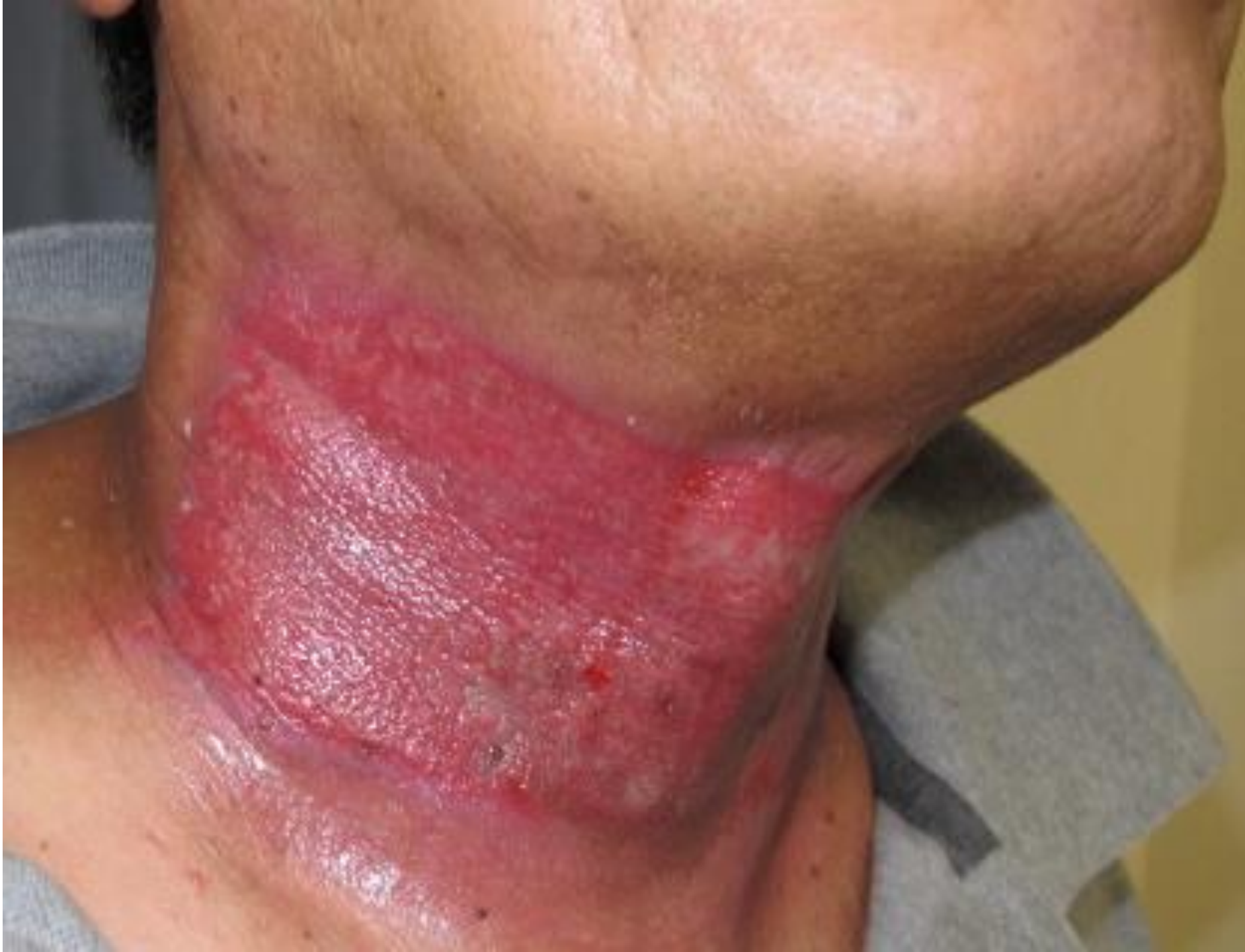


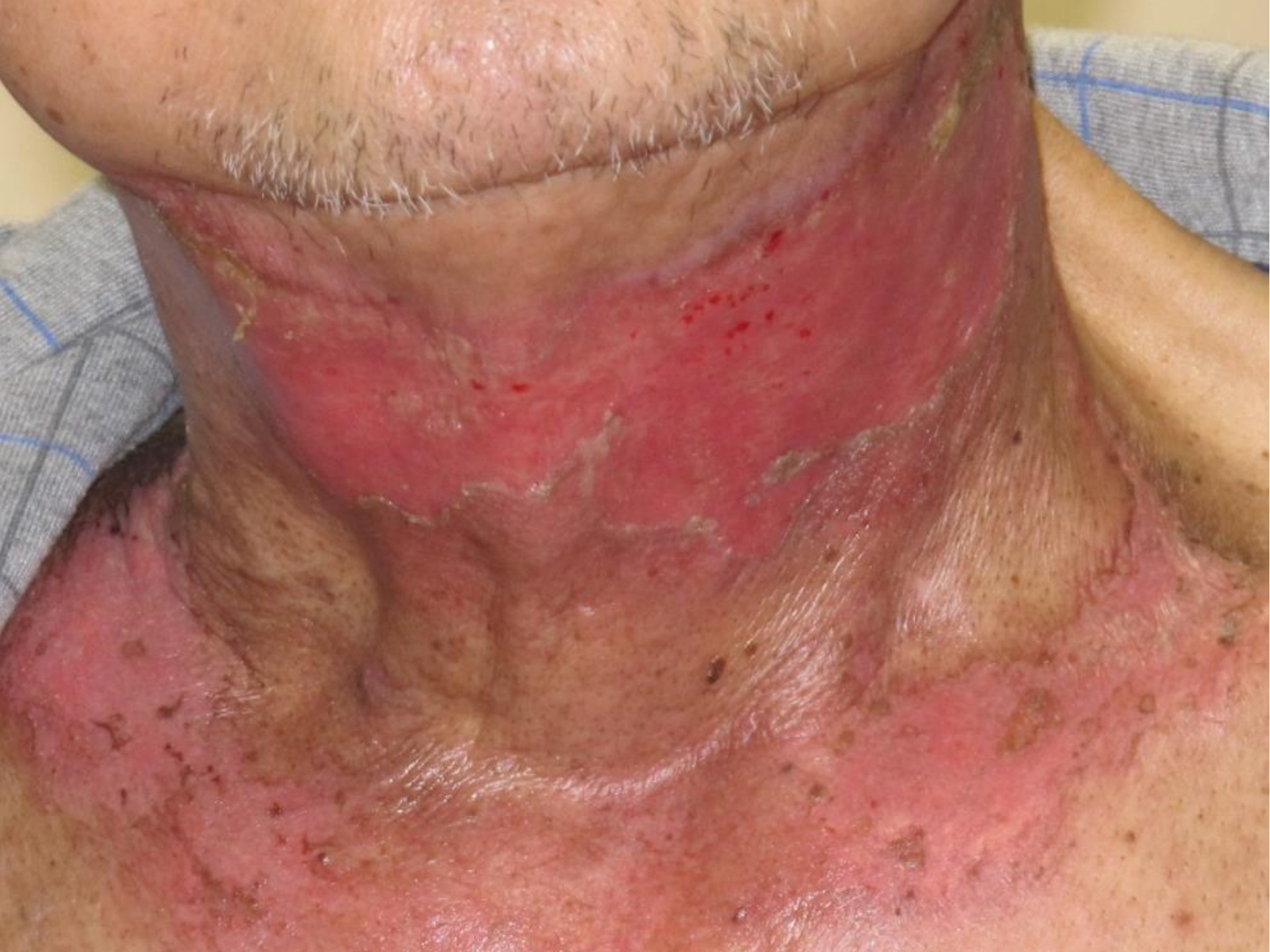

**Bleeding induced by
minor trauma or abrasion**



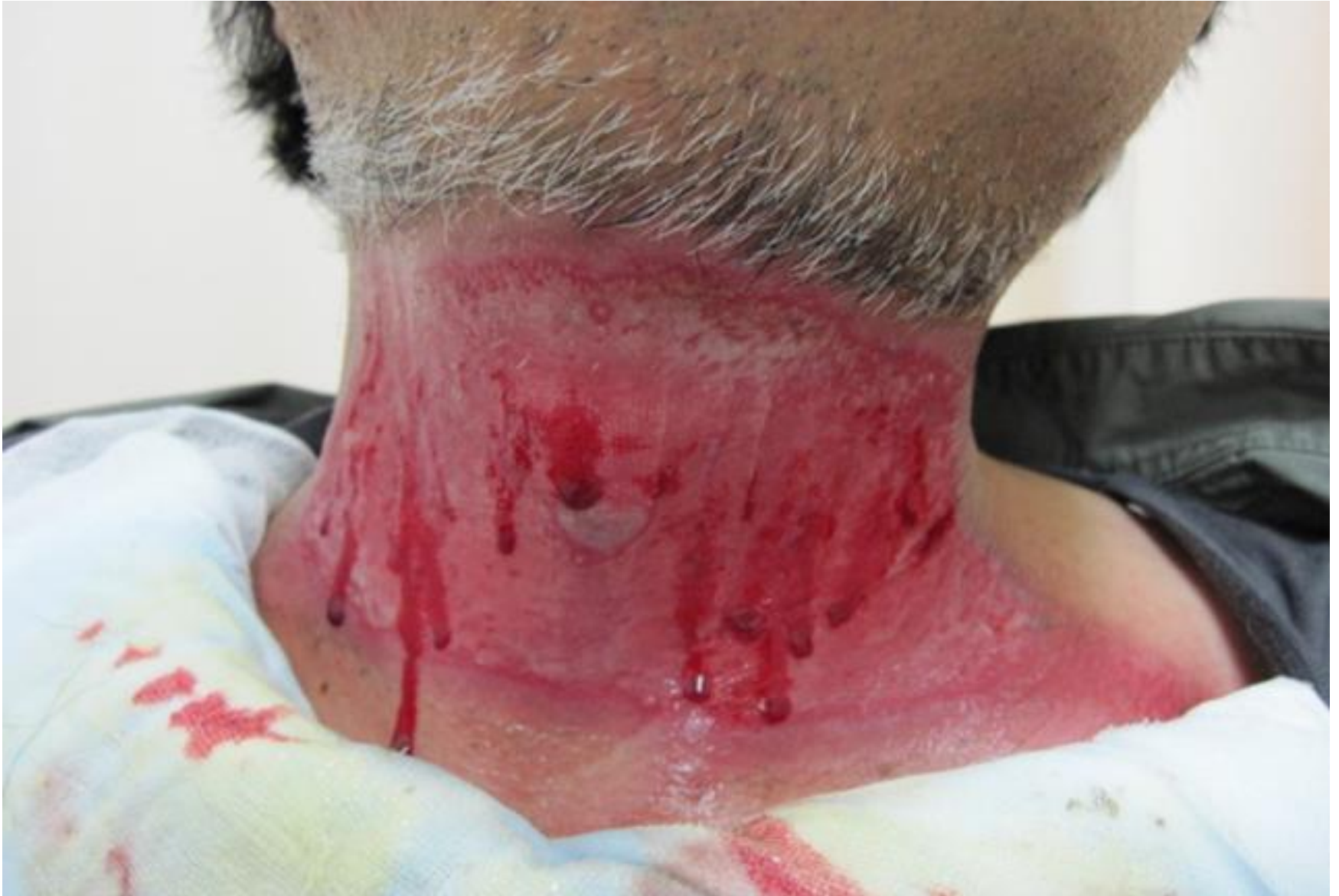



Gr.4

Radiation Dermatitis

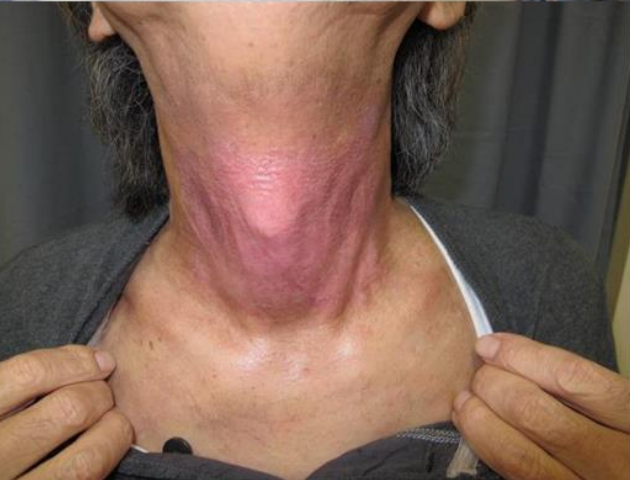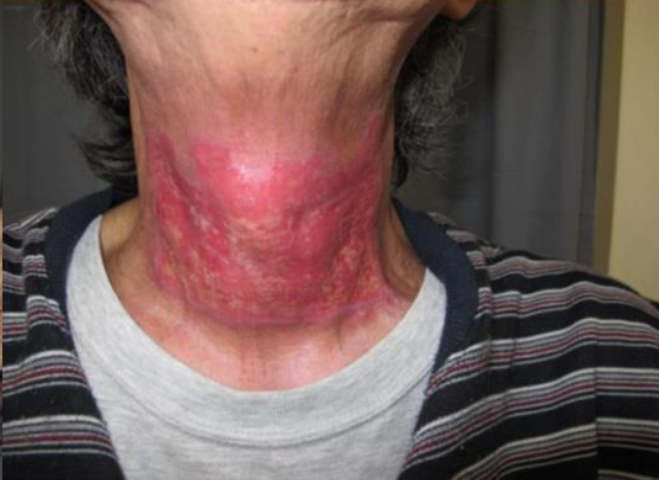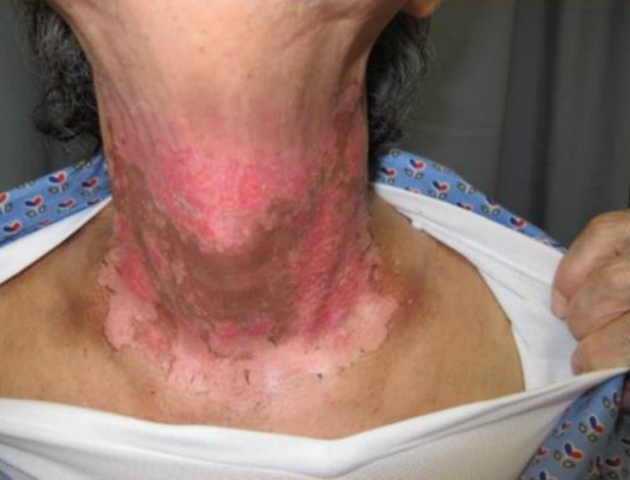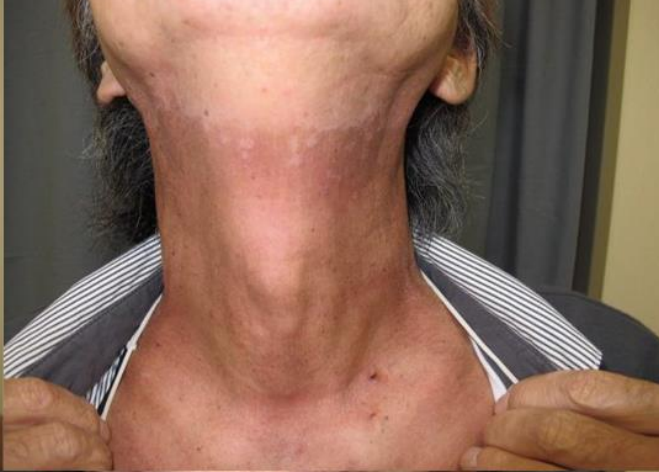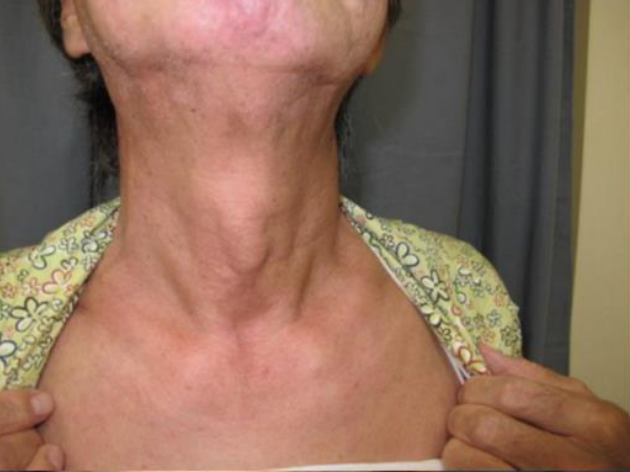Spontaneous bleeding from involved site;



Skin necrosis or ulceration of full thickness
Skin graft indicated

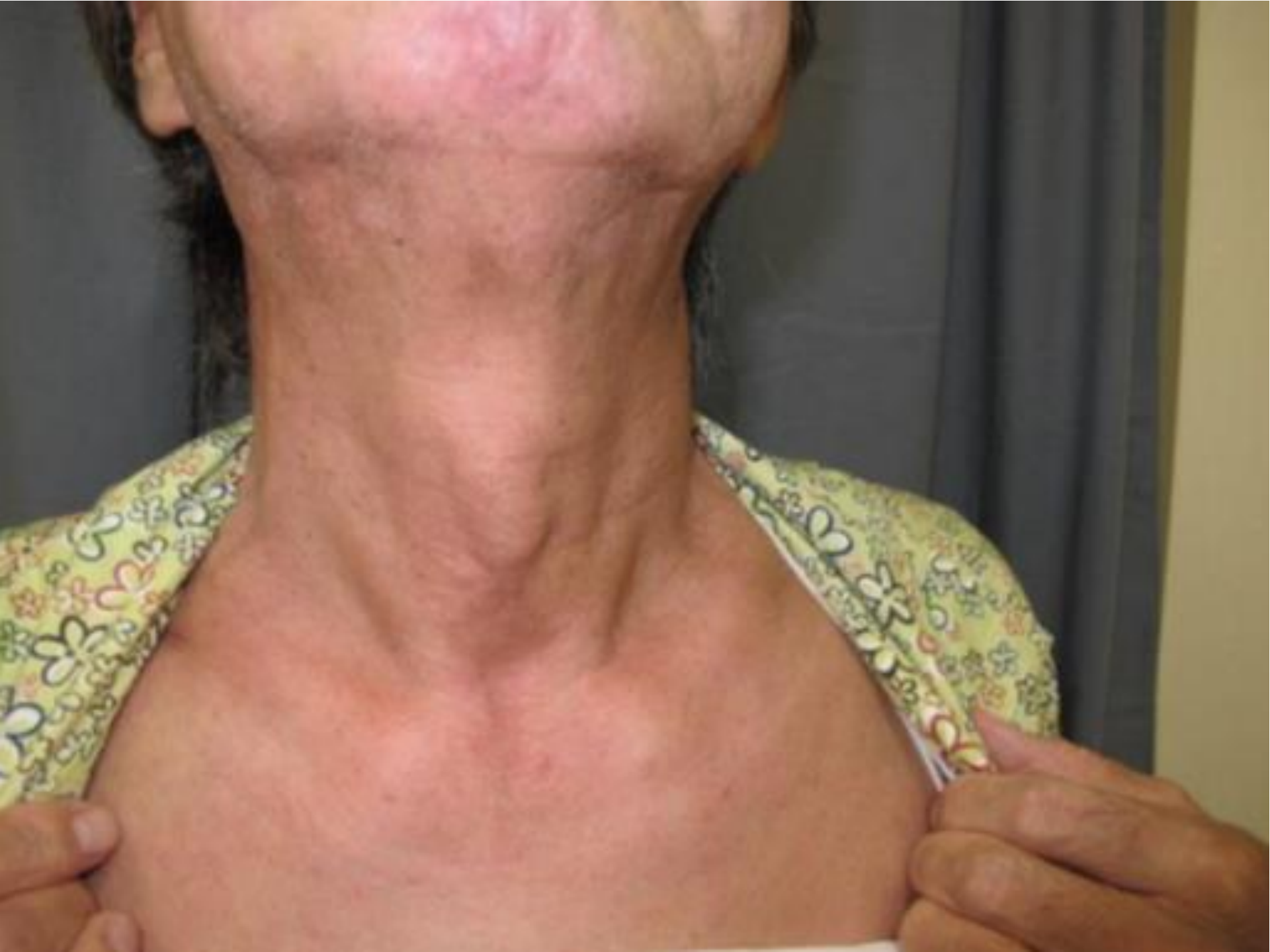No typical photograph

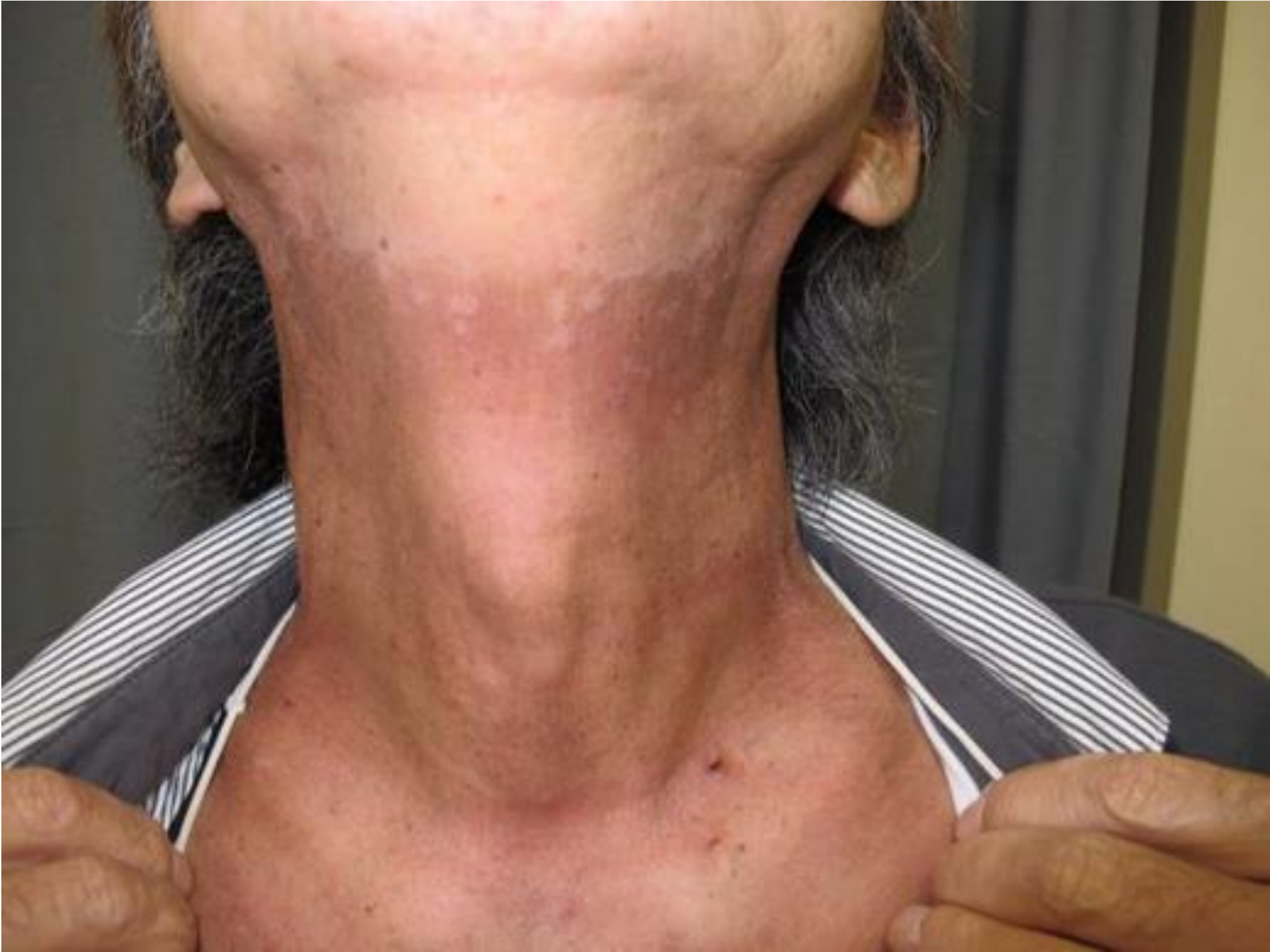Series photographs

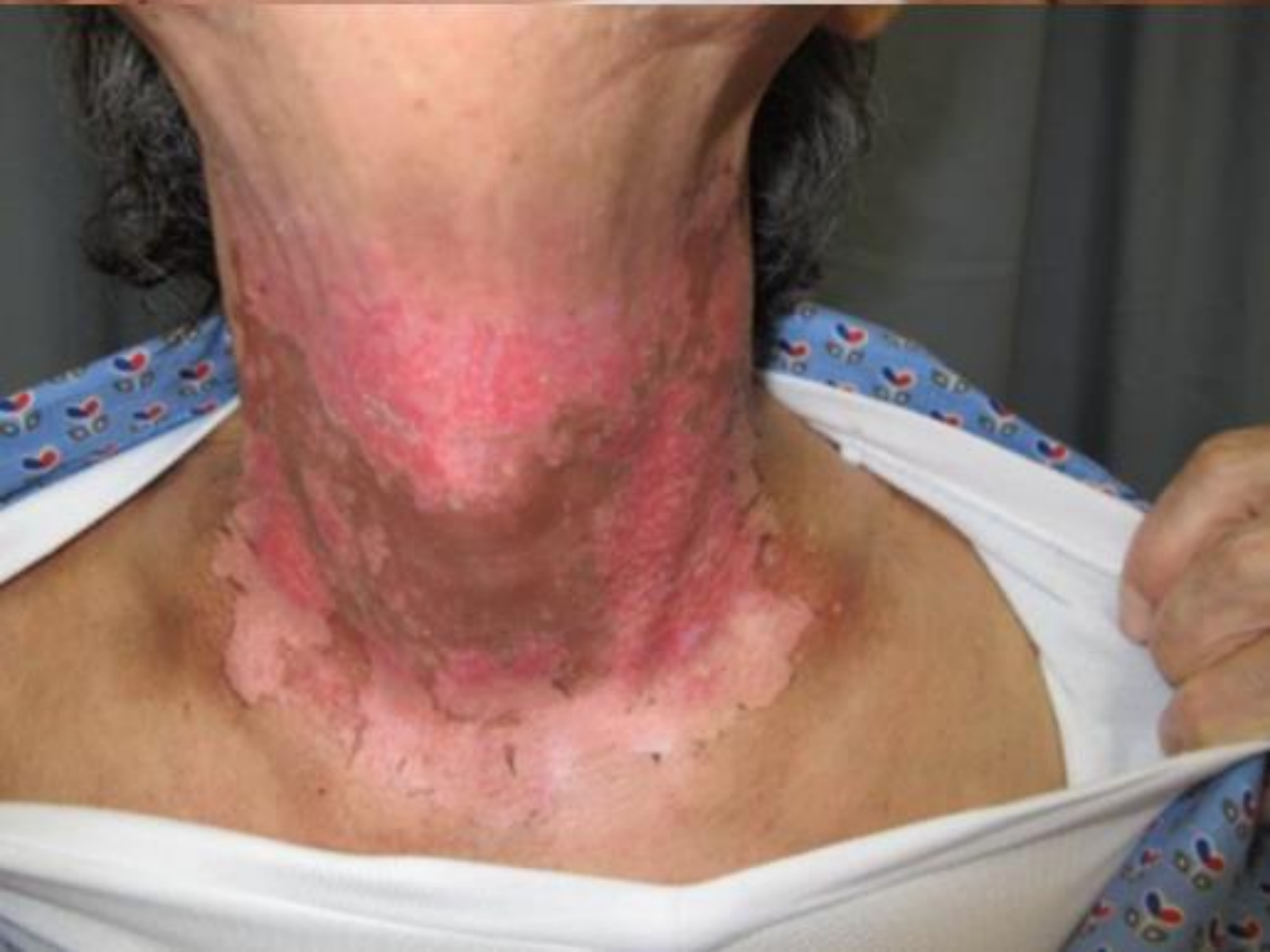

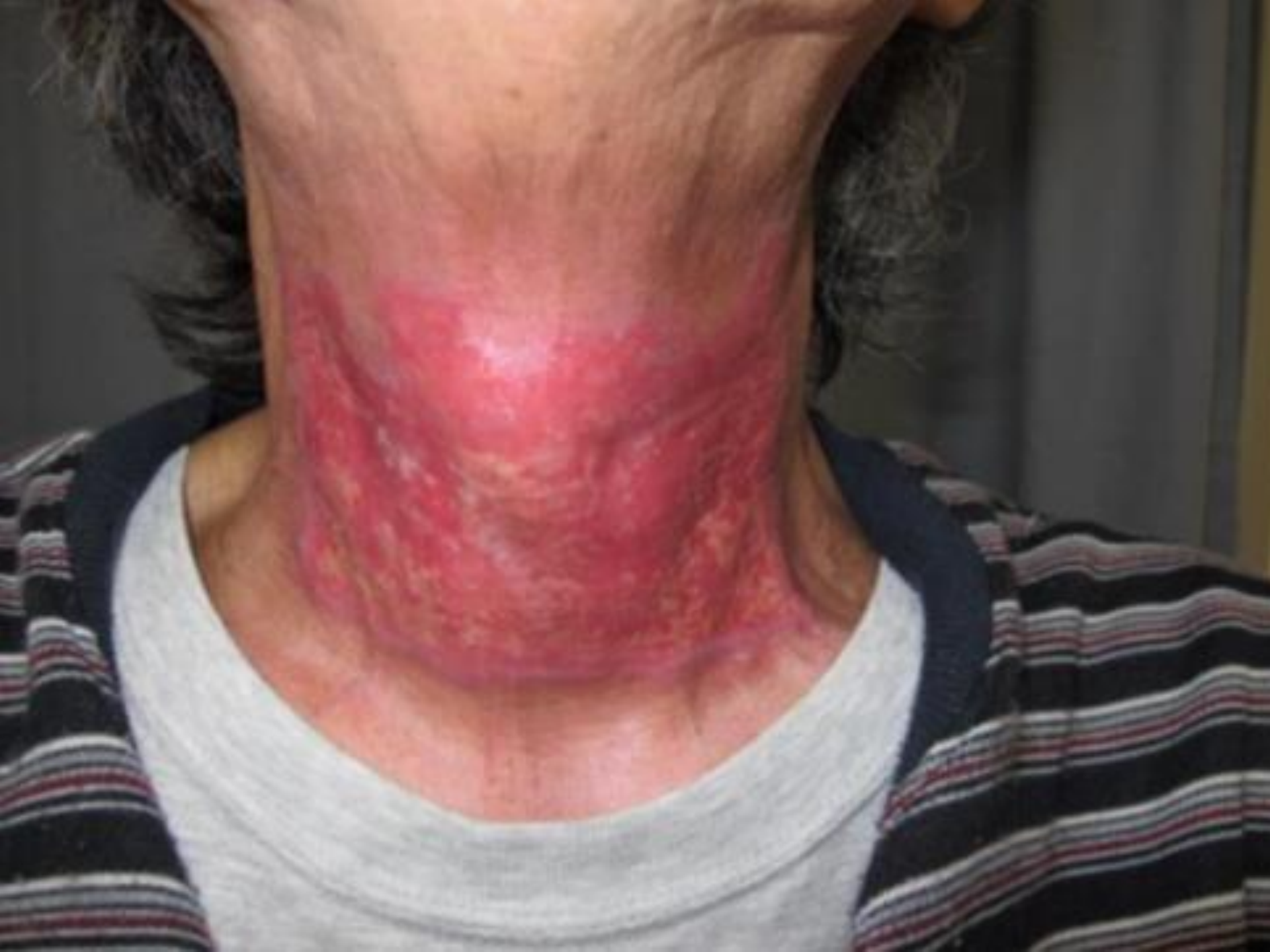**RT alone
66Gy/33fr**

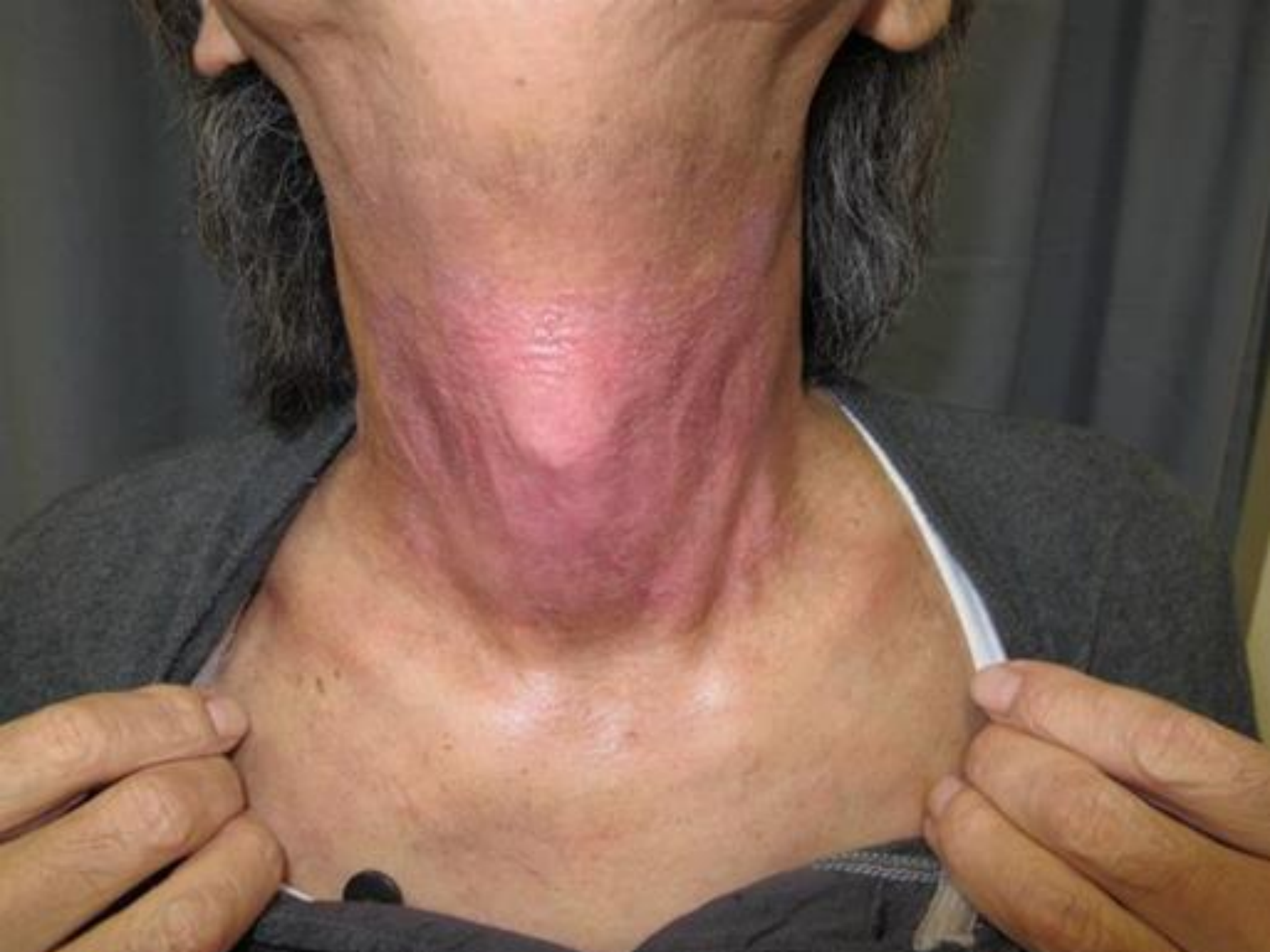14Gy	38Gy
54Gy	66Gy
10 days after RT	

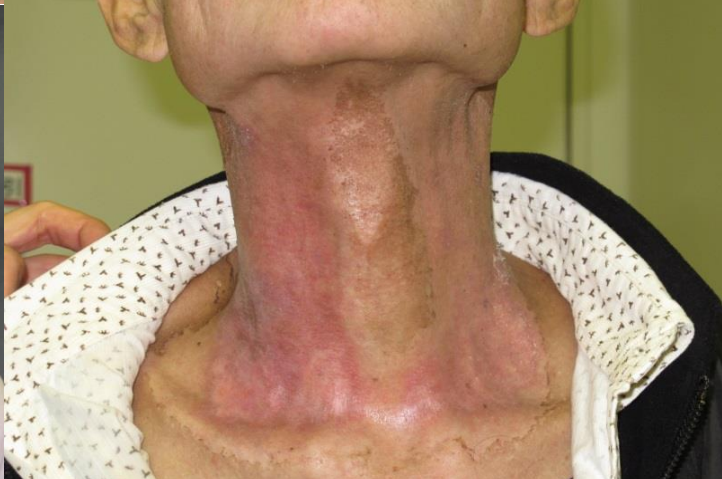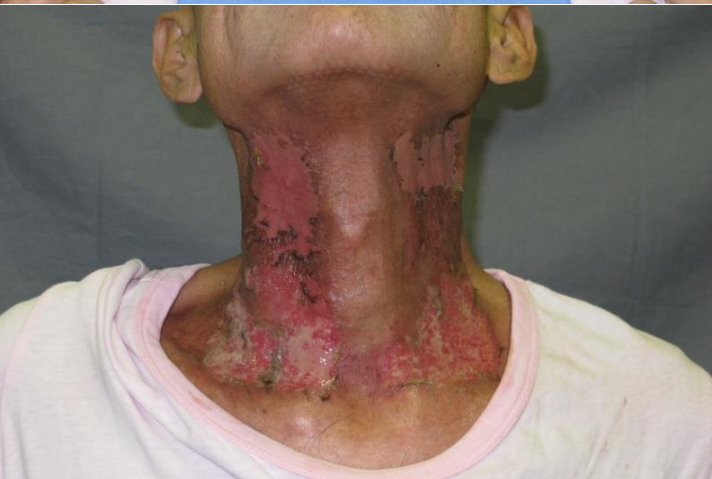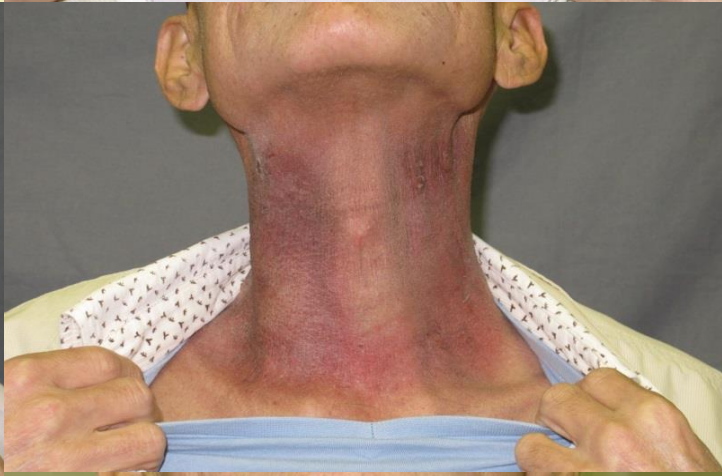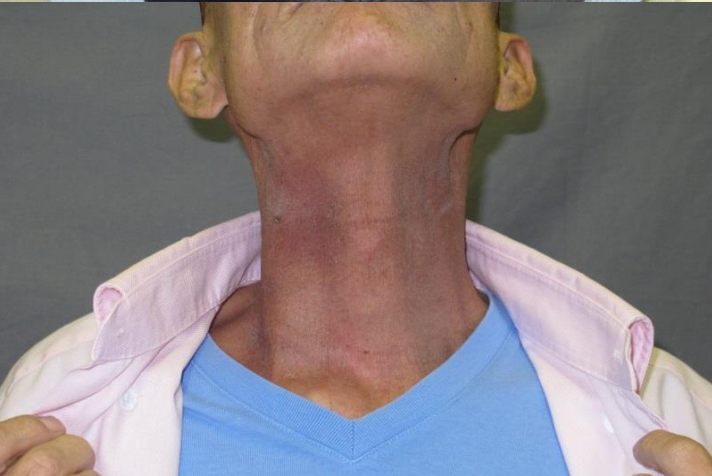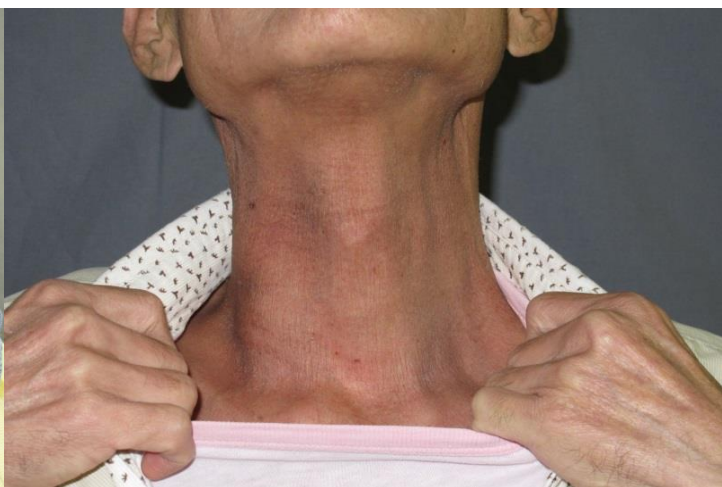




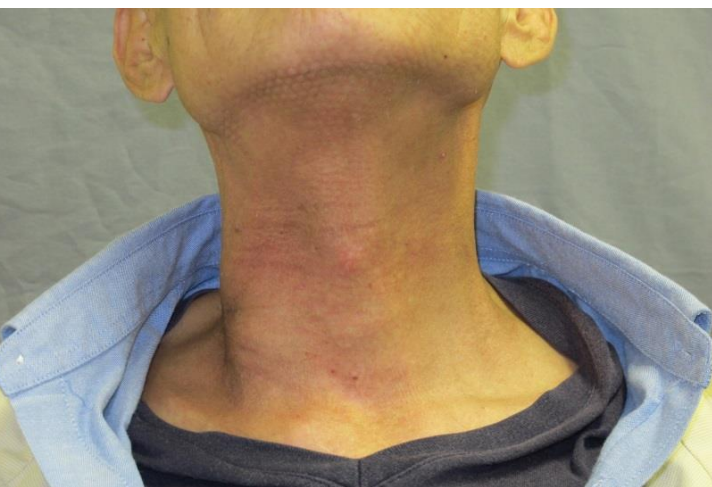







CDDP+RT 70Gy/35fr

32Gy	40Gy
52Gy	60Gy
70Gy	13 days after RT











